The Gross Anatomy Of The Brain

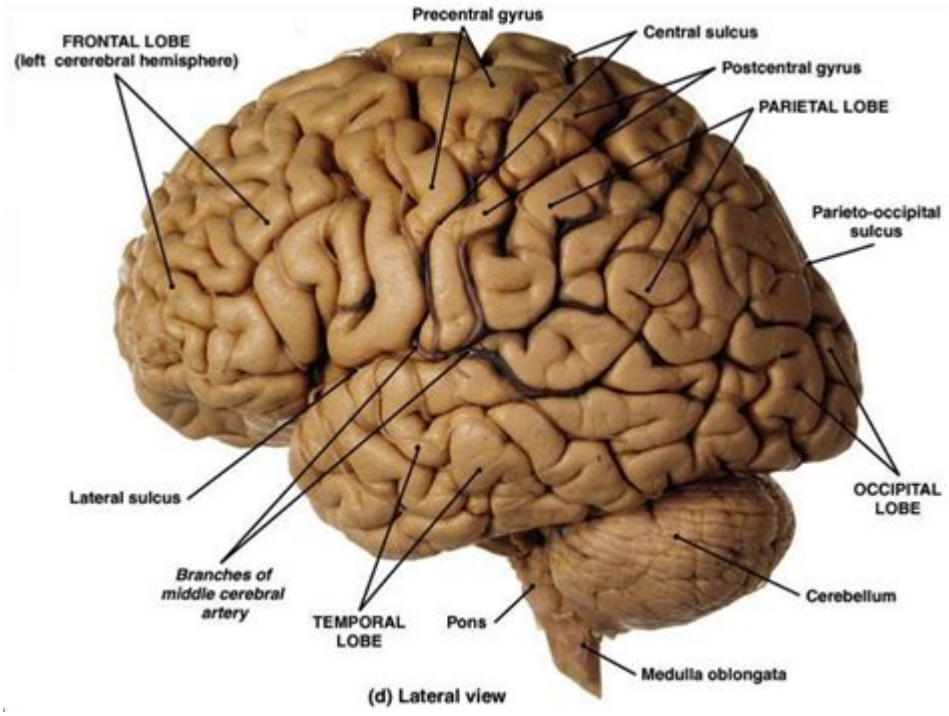

The gross anatomy of the brain is a fascinating topic that delves into the structure and organization of one of the most complex organs in the human body. The brain is responsible for regulating a myriad of functions, from basic survival processes to complex cognitive tasks. This article will explore the various components of the brain, its major divisions, and their respective functions, providing a comprehensive overview of its gross anatomy.

Overview of the Brain

The human brain weighs about 1.4 kilograms (approximately 3 pounds) and is composed of approximately 86 billion neurons. It is encased in the protective skull and is surrounded by cerebrospinal fluid (CSF), which serves as a cushion against physical trauma. The brain is generally divided into several anatomical regions, each associated with different functions.

Major Divisions of the Brain

The brain can be broadly categorized into three major divisions: the forebrain, midbrain, and hindbrain. Each of these divisions contains various structures that play distinct roles in the overall functioning of the brain.

Forebrain

The forebrain is the largest part of the brain and is responsible for higher cognitive functions, sensory perception, and the regulation of emotions. It is subdivided into two main parts: the cerebrum and the diencephalon.

- Cerebrum: The cerebrum comprises the right and left hemispheres, which are connected by the corpus callosum. Each hemisphere is further divided into four lobes:
- Frontal Lobe: Involved in decision-making, problem-solving, and controlling behavior and emotions.
- Parietal Lobe: Processes sensory information such as touch, temperature, and pain.
- Temporal Lobe: Responsible for auditory perception and is critical for memory and language comprehension.
- Occipital Lobe: The visual processing center, responsible for interpreting visual stimuli.

- Diencephalon: This region lies beneath the cerebrum and is composed of the thalamus, hypothalamus, and epithalamus.
- Thalamus: Acts as the relay station for sensory information, except for olfactory signals.
- Hypothalamus: Regulates homeostasis, including body temperature, hunger, thirst, and circadian rhythms. It also controls the pituitary gland, linking the nervous system to the endocrine system.
- Epithalamus: Includes the pineal gland, which secretes melatonin and regulates sleep-wake cycles.

Midbrain

The midbrain, or mesencephalon, is a small region located below the thalamus and above the pons. It plays crucial roles in vision, hearing, motor control, sleep/wake cycles, and the regulation of temperature. Key structures in the midbrain include:

- Tectum: Contains the superior and inferior colliculi, which are involved in visual and auditory reflexes, respectively.
- Tegmentum: Contains various nuclei, including the red nucleus and substantia nigra, which are essential for motor control and coordination.

Hindbrain

The hindbrain, or rhombencephalon, is located at the base of the brain and includes the pons, medulla oblongata, and cerebellum. It is responsible for regulating many involuntary functions and coordinating movement.

- Cerebellum: Often referred to as the "little brain," it is crucial for balance, posture, and the coordination of voluntary movements. It receives input from sensory systems and other parts of the brain to fine-tune motor activity.
- Pons: Acts as a bridge between the cerebrum and cerebellum, as well as between the various parts of the brain. It plays a role in regulating breathing and sleep cycles.
- Medulla Oblongata: The lowest part of the brainstem, it controls vital autonomic functions such as heart rate, blood pressure, and respiration.

Surface Features of the Cerebrum

The surface of the cerebrum is characterized by its convoluted appearance, which increases the surface area and allows for greater neuronal density. The key surface features include:

- Gyri: The raised ridges or folds of the brain tissue.
- Sulci: The grooves or indentations between the gyri.
- Fissures: Deep grooves that separate large regions of the brain. The most notable fissure is the longitudinal fissure, which divides the brain into the left and right hemispheres.

Protective Structures of the Brain

The brain is safeguarded by several protective structures that help maintain its integrity and function:

Skull

The brain is encased in the bony skull, which provides a rigid structure to protect against physical damage. The skull consists of several bones fused together, including the frontal, parietal, temporal, and occipital bones.

Meninges

The meninges are three layers of protective tissue that surround the brain and spinal cord:

1. Dura Mater: The outermost and toughest layer, it provides the most protection.
2. Arachnoid Mater: The middle layer, which has a web-like appearance and contains the cerebrospinal fluid.
3. Pia Mater: The innermost layer that closely adheres to the brain's

surface, providing additional protection and nourishment.

Cerebrospinal Fluid (CSF)

CSF circulates within the subarachnoid space between the arachnoid mater and pia mater. It serves several critical functions:

- Provides buoyancy to the brain, reducing its effective weight and preventing damage from impacts.
- Acts as a shock absorber.
- Maintains homeostasis of the brain's internal environment by transporting nutrients and removing waste products.

Blood Supply to the Brain

The brain requires a significant amount of blood flow to meet its metabolic needs. The primary sources of blood supply are:

- Internal Carotid Arteries: Supply the anterior and middle parts of the brain.
- Vertebral Arteries: Merge to form the basilar artery, which supplies the posterior part of the brain.
- Circle of Willis: A circular network of arteries at the base of the brain that provides collateral circulation, ensuring that blood flow continues even if one of the main arteries becomes blocked.

Conclusion

In conclusion, the gross anatomy of the brain is a complex and intricate subject that encompasses various structures and functions. Understanding the major divisions of the brain, its surface features, protective structures, and blood supply is essential for appreciating how this remarkable organ works to regulate and coordinate the myriad functions that sustain life. As research advances, our understanding of the brain continues to evolve, unlocking secrets that may one day lead to new treatments for neurological disorders and enhance our knowledge of human cognition and behavior.

Frequently Asked Questions

What are the main structures of the gross anatomy of

the brain?

The main structures include the cerebrum, cerebellum, brainstem (which consists of the midbrain, pons, and medulla oblongata), and the limbic system.

How is the cerebrum divided, and what are its functions?

The cerebrum is divided into two hemispheres (left and right) and further into four lobes: frontal (responsible for reasoning and planning), parietal (processing sensory information), temporal (involved in memory and auditory processing), and occipital (responsible for vision).

What role does the cerebellum play in brain function?

The cerebellum is crucial for coordination, balance, and fine motor control, as well as for processing sensory information related to movement.

What is the function of the brainstem?

The brainstem controls essential life functions such as breathing, heart rate, and blood pressure, and it serves as a pathway for communication between the brain and the spinal cord.

What is the limbic system, and what functions does it serve?

The limbic system is a complex set of structures including the hippocampus, amygdala, and hypothalamus, and it plays a key role in emotion regulation, memory formation, and the body's response to stress.

How does the structure of the brain relate to its function?

The brain's structure supports its functions through specialized regions; for example, the folded surface of the cerebral cortex increases surface area for neural connections, enhancing cognitive abilities, while different brain regions are specialized for specific sensory and motor tasks.

The Gross Anatomy Of The Brain

gross是什么意思? - 百度知道

gross根据词性不同有不同意思，词性及意思分别为： 1、adj. 总的;毛的;严重的;令人不快的;令人恶心的;使人厌恶的 2、adv. 总共;全部 3、v. 总收入为;总共赚得 4、n. 一罗 (144个); (尤指影片的)毛收入，总 …

gross和**total**的区别 **-** 百度知道

Nov 13, 2024 · Gross和Total这两个词在英语中都有“总额”的意思，但具体用法和含义有所不同。Gross通常用于表示总收入或未经减去任何费用之前的总额，例如，Gross Income（总收入） …

gross和**net**区别 **-** 百度知道

Sep 12, 2024 · gross和net区别Net和Gross的区别在于计算方式和所涵盖的范围。 Gross是指总额，包括所有相关项目的总和；而Net是指净额，扣除了相关项目后的余额。

*N.W*和*G.W*具体定义是什么? _百度知道

N.W.是英文Net Weight的缩写，翻译成中文上净重。是指商品本身的重量，即除去包装物后的商品实际重量。 G.W.是英文 Gross Weight 的缩写，翻译成中文上毛重。是指货物连同它的包装的重量。所 …

毛重G.W.（gross weight）跟净重N.W.（net weight）有什么区别? _百 …

Nov 19, 2011 · 毛重G.W.（gross weight）跟净重N.W.（net weight）有什么区别? 毛重就是商品本身的重量加上包装物的重量。净重只是商品本身的重量。毛重和净重的定义与计算方法：一、定义：毛 …

gross是什么意思? **-** 百度知道

gross根据词性不同有不同意思，词性及意思分别为： 1、adj. 总的;毛的;严重的;令人不快的;令人恶心的;使人厌恶的 2、adv. 总共;全部 3、v. 总收入为;总共赚得 4、n. 一罗 (144个); (尤指影片 …

gross和total的区别 - 百度知道

Nov 13, 2024 · Gross和Total这两个词在英语中都有“总额”的意思，但具体用法和含义有所不同。Gross通常用于表示总收入或未经减去任何费用之前的总额，例如，Gross Income（总收入） …

gross和**net**区别 **-** 百度知道

Sep 12, 2024 · gross和net区别Net和Gross的区别在于计算方式和所涵盖的范围。 Gross是指总额，包括所有相关项目的总和；而Net是指净额，扣除了相关项目后的余额。

*N.W*和*G.W*具体定义是什么? _百度知道

N.W.是英文Net Weight的缩写，翻译成中文上净重。是指商品本身的重量，即除去包装物后的商品实际重量。 G.W.是英文 Gross Weight 的缩写，翻译成中文上毛重。是指货物连同它的包装的 …

毛重G.W.（gross weight）跟净重N.W.（net weight）有什么区 …

Nov 19, 2011 · 毛重G.W.（gross weight）跟净重N.W.（net weight）有什么区别? 毛重就是商品本身的重量加上包装物的重量。净重只是商品本身的重量。毛重和净重的定义与计算方法：一、 …

请问*operating Margin*和*gross Margin*到底是什么意思? _百度知道

Sep 7, 2024 · 请问operating Margin和gross Margin到底是什么意思? 在理解和评估公司的财务健康状况时，两个关键比率：operating Margin（营业毛利）和gross Margin（毛利率）起着至 …

gross profit 是怎么计算的**?** 和**sale** 以及 **operating profit**的区别 谢 **…**

二、三者含义不同： 1、gross profit是毛利的意思。 2、sale是出售，卖的意思，也有销售额的含义。 3、operating profit是营业利润的意思。营业利润是指企业从事生产经营活动中取得的利润，…

gross sales是什么意思？_百度知道

gross sales是什么意思？ grosssales总销售额netsales净销售额区别：二者的范围和意义不同：净销售额是购货单位最终承诺结算额，也就是真正算得上是销售收入的数额。

net profit与gross profit有什么区别呢？- 百度知道

May 18, 2024 · Net profit与gross profit的主要区别在于它们计算利润时考虑的成本类型不同。Net profit，即净利润，是指企业在一定时期内经营活动的最终财务成果。它反映了企业在扣除所 …

gross palmar grasp - WordReference Forums

May 15, 2007 · Necesito traducir la siguiente frase en el contexto que se da. Se trata de un niño que toma objetos con la mano en diversas formas: Andy uses a variety of grasps, including a …

Explore the gross anatomy of the brain in detail. Uncover its structures

Back to Home