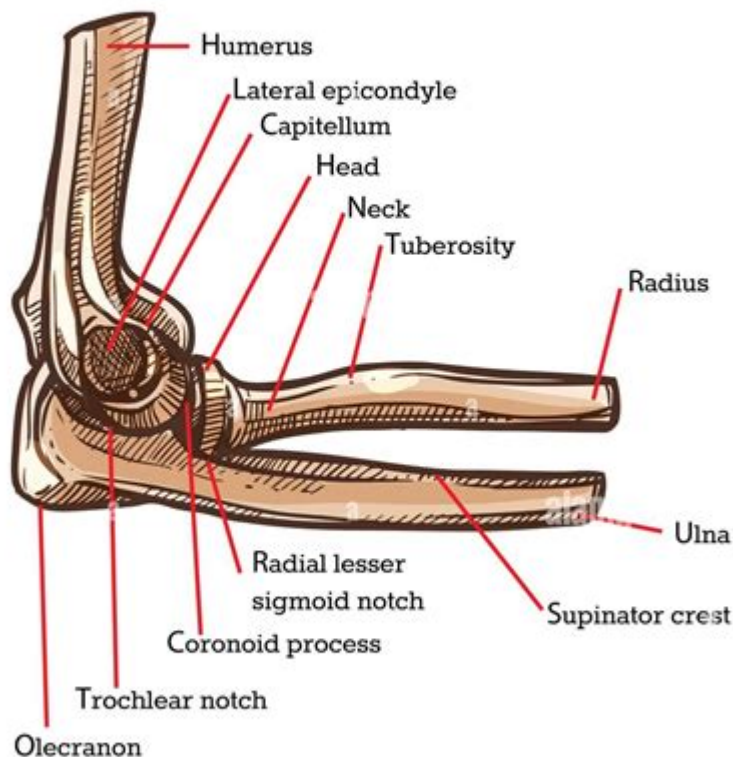


Picture Of Elbow Anatomy

BONES OF ELBOW



alamy

Image ID: 2EMPRC3
www.alamy.com

Picture of elbow anatomy is a valuable resource for understanding the complex structure of the elbow joint, which plays a crucial role in the functioning of the upper limb. The elbow connects the humerus (the upper arm bone) to the radius and ulna (the forearm bones), allowing for a wide range of motion including flexion, extension, and rotation. This article delves into the intricate anatomy of the elbow, examining its bones, ligaments, muscles, and overall function. Understanding the anatomy of the elbow is essential for medical professionals, athletes, and anyone interested in the mechanics of the human body.

Overview of the Elbow Joint

The elbow joint is classified as a hinge joint, primarily allowing for flexion and extension. It also possesses limited rotational capabilities, enabling the forearm to rotate in conjunction with the upper arm.

Components of the Elbow Joint

1. Bones:

- Humerus: The largest bone of the upper arm, which forms the upper part of the elbow joint.
- Radius: The lateral bone of the forearm, situated on the same side as the thumb.
- Ulna: The medial bone of the forearm, located on the opposite side of the thumb.

2. Articular Surfaces:

- The elbow consists of three main articulations:
- Humero-ulnar joint: The primary joint for flexion and extension.
- Humero-radial joint: Allows for some rotational movement.
- Proximal radioulnar joint: Facilitates the rotation of the forearm.

3. Ligaments:

- Ulnar collateral ligament (UCL): Provides stability on the medial side of the elbow.
- Radial collateral ligament (RCL): Offers support on the lateral side.
- Annular ligament: Encircles the head of the radius, allowing for rotational movement during supination and pronation.

Detailed Anatomy of Elbow Components

Understanding the individual components of the elbow joint is essential for grasping its overall functionality.

Bones of the Elbow

1. Humerus:

- The distal end of the humerus features two prominent projections known as epicondyles:
- Medial epicondyle: Serves as the attachment point for several forearm flexor muscles.
- Lateral epicondyle: Serves as the attachment point for forearm extensor muscles.
- The trochlea and capitulum are the joint surfaces that articulate with the ulna and radius, respectively.

2. Radius and Ulna:

- The ulna has a C-shaped structure at its proximal end called the olecranon, which forms the point of the elbow and serves as a lever arm for muscle action.
- The radius has a disc-shaped head that allows it to rotate within the annular ligament at the proximal radioulnar joint.

Ligaments of the Elbow

The ligaments serve as stabilizers for the elbow joint, preventing excessive movements that could lead to injuries.

1. Ulnar Collateral Ligament (UCL):

- Composed of three bands: anterior, posterior, and transverse.
- The anterior band is the strongest and most critical for stability during throwing motions.

2. Radial Collateral Ligament (RCL):

- This ligament is less robust than the UCL and provides lateral stability to the elbow.

3. Annular Ligament:

- Forms a ring around the head of the radius, allowing for smooth rotation during forearm movements.

Muscles Surrounding the Elbow

The muscles surrounding the elbow joint are responsible for its movement and stability. They can be categorized based on their primary actions.

Flexor Muscles

1. Biceps Brachii:

- Originates from the scapula and attaches to the radius.
- Functions to flex the elbow and supinate the forearm.

2. Brachialis:

- Located beneath the biceps, it is the primary flexor of the elbow.

3. Brachioradialis:

- A forearm muscle that assists in flexing the elbow when the forearm is in a neutral position.

Extensor Muscles

1. Triceps Brachii:

- The main extensor of the elbow, originating from the scapula and humerus and inserting on the olecranon of the ulna.

2. Anconeus:

- A small muscle that assists the triceps in extending the elbow, located at the posterior aspect of the elbow.

Rotational Muscles

1. Pronator Teres:

- Assists in pronating the forearm, allowing the palm to face downwards.

2. Supinator:

- Opposes the action of the pronator teres, enabling supination of the forearm.

Functional Anatomy of the Elbow

The elbow joint functions in a coordinated manner, allowing for intricate movements that are critical for daily activities and athletic performance.

Range of Motion

The elbow allows for several ranges of motion, categorized as follows:

1. Flexion: Bending the elbow to bring the forearm closer to the upper arm, typically reaching an angle of approximately 135 to 150 degrees.
2. Extension: Straightening the elbow, returning to a neutral position.
3. Pronation and Supination: The forearm's ability to rotate, with the palm facing down (pronation) or up (supination).

Common Injuries and Conditions

Understanding elbow anatomy is crucial for recognizing potential injuries and conditions. Some common issues include:

1. Tennis Elbow (Lateral Epicondylitis):
 - Caused by overuse of the forearm extensor muscles, leading to pain on the lateral side of the elbow.
2. Golfer's Elbow (Medial Epicondylitis):
 - Involves inflammation of the tendons on the medial side of the elbow, often due to repetitive wrist flexion.
3. Ulnar Collateral Ligament Injuries:
 - Common in athletes who perform repetitive overhead motions, such as pitchers in baseball.
4. Fractures:
 - Fractures of the humerus, radius, or ulna can occur due to falls or trauma, often requiring medical intervention.

Conclusion

A picture of elbow anatomy provides a visual representation of the complex structures within the

elbow joint, enhancing our understanding of its function and significance in daily life. The interplay between the bones, ligaments, and muscles enables the elbow to perform a variety of movements essential for upper limb activities, from simple tasks like lifting objects to complex athletic maneuvers. By recognizing the anatomy and potential injuries associated with the elbow, individuals can better appreciate the importance of this joint and the need for proper care and rehabilitation when injuries occur. Understanding elbow anatomy not only aids in medical diagnosis and treatment but also enhances athletic training and performance, ensuring the elbow remains a vital component of human mobility and functionality.

Frequently Asked Questions

What are the main bones that make up the elbow joint?

The main bones that make up the elbow joint are the humerus, radius, and ulna.

What is the anatomical term for the outer part of the elbow?

The anatomical term for the outer part of the elbow is the lateral epicondyle.

What ligaments are associated with elbow anatomy?

The key ligaments associated with elbow anatomy include the ulnar collateral ligament, radial collateral ligament, and annular ligament.

What muscles are primarily involved in elbow flexion?

The primary muscles involved in elbow flexion are the biceps brachii and brachialis.

What is the role of the olecranon in elbow anatomy?

The olecranon is the bony prominence of the ulna that forms the point of the elbow and serves as an attachment site for muscles.

How does the elbow joint allow for movement?

The elbow joint allows for movement primarily through flexion and extension, as well as a limited degree of rotation.

What is the function of the joint capsule in the elbow?

The joint capsule surrounds the elbow joint, providing stability and containing synovial fluid for lubrication.

What are common injuries associated with elbow anatomy?

Common injuries associated with elbow anatomy include tennis elbow (lateral epicondylitis) and golfer's elbow (medial epicondylitis).

How can imaging techniques help in understanding elbow anatomy?

Imaging techniques like X-rays, MRIs, and CT scans can help visualize the structures of the elbow, identify injuries, and plan treatment.

What is the significance of the carrying angle in elbow anatomy?

The carrying angle is the angle formed between the humerus and forearm when the arm is extended, and it helps with the function and movement of the arm.

Find other PDF article:

<https://soc.up.edu.ph/36-tag/files?ID=cSe36-2837&title=lara-implicit-bias-training-free.pdf>

Picture Of Elbow Anatomy

photo **photograph** **picture** -

photo picture 2. Photo

Windows 11 -

Sergey Tkachenko How to remove “Learn more about this picture” icon in Windows 11 Winaero regedit

movie **film** **motion picture** -

Jan 5, 2024 · movie film motion picture Movie Film Motion Picture “” 1. Movie Film Movie Film

picture **photo** -

picture photo 1 picture photo 2 picture “” imagine photo 3 picture ...

URL -

API URL URL...

image **picture** -

image picture 1 image ['ɪmɪdʒ] picture ['pɪktʃə(r)] ['pɪktʃər] 2 image n. () picture n. v. ...

markdown -

markdown HTML

sci *Graphical Abstract* -

IF and Short Abstract figure
 ...

chart **diagram** **graph** **figure** ...

chart: A chart is a diagram, picture, or graph which is intended to make information easier to understand. **chart** **diagram** **picture** **graph** **diagram**: A diagram is a simple drawing which consists mainly of lines and is used, for example, to explain how a machine works.

CAD3 -

Sep 30, 2019 · CAD!

photo **photograph** **picture** -

photo **picture** 2. **Photo**

Windows 11 -

Sergey Tkachenko How to remove “Learn more about this picture” icon in Windows 11 Winaero regedit

movie **film** **motion picture** -

Jan 5, 2024 · **movie** **film** **motion picture** **Movie** **Film** **Motion Picture** “” 1. **Movie** **Film** **Movie** **Film**

picture **photo** -

picture **photo** 1 **picture** **photo** 2 **picture** “” **imagine** **photo** 3 **picture** ...

URL -

API **URL** **URL**...

image **picture** -

image **picture** 1 **image** ['ɪmɪdʒ] **picture** ['pɪktʃə (r)] **picture** ['pɪktʃər] 2 **image** n. () **picture** n. v. ...

markdown -

markdown **HTML**

sci *Graphical Abstract* -

IF and Short Abstract figure
 ...

chart **diagram** **graph** **figure** ...

chart: A chart is a diagram, picture, or graph which is intended to make information easier to understand. **chart** **diagram** **picture** **graph** **diagram**: A diagram is a simple drawing which consists mainly of lines and is used, for example, to explain how a machine works.

CAD3 -

Sep 30, 2019 · CAD!

Explore detailed pictures of elbow anatomy to enhance your understanding of this complex joint. Learn more about its structure and function today!

[Back to Home](#)