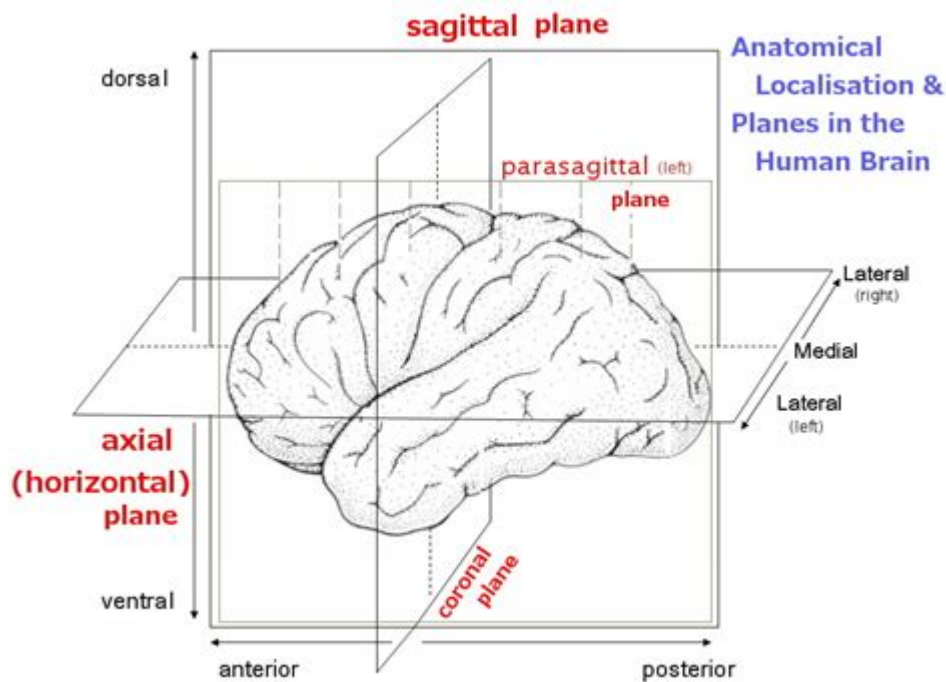


Planes Of The Head Anatomy



Planes of the head anatomy are crucial for understanding the complex structures that comprise the human head. Anatomy is fundamentally about organization; the planes help medical professionals and students navigate the intricate relationships between various anatomical structures. Understanding these planes is essential for diagnosing conditions, planning surgeries, and conducting medical imaging. This article will explore the primary anatomical planes of the head, their significance, and their applications in clinical practice.

Understanding Anatomical Planes

Anatomical planes are imaginary lines that divide the body into sections, providing a standardized way to describe locations and movements. In the context of head anatomy, these planes help professionals communicate effectively about the spatial relationships between different structures. The primary anatomical planes include:

1. Sagittal Plane
2. Coronal Plane
3. Transverse Plane

Each of these planes serves a unique purpose and helps in identifying the orientation of structures within the head.

Sagittal Plane

The sagittal plane divides the body into left and right halves. It runs vertically from the front to the back of the body, allowing for the examination of structures in a lateral view.

- Midsagittal Plane: This specific plane runs directly down the center of the body, dividing it into equal left and right halves.
- Parasagittal Plane: Any sagittal plane that is not in the exact midline but still divides the body into unequal left and right portions.

Significance in Head Anatomy:

The sagittal plane is particularly useful for studying bilateral structures such as the eyes, ears, and nasal passages. It allows clinicians to assess symmetry in these structures, which is essential in diagnosing conditions like:

- Asymmetry in craniofacial anomalies
- Deviations in the nasal septum
- Dental malocclusions

Coronal Plane

The coronal plane, also known as the frontal plane, divides the body into anterior (front) and posterior (back) sections. This plane runs vertically and is perpendicular to the sagittal plane.

Significance in Head Anatomy:

The coronal plane is vital for evaluating structures such as:

- The forehead and facial structures
- The positioning of the eyes and ears in relation to the skull
- The relationship between the nasal cavity and oral cavity

Medical imaging techniques like MRI and CT scans often utilize the coronal plane to provide detailed views of the facial and cranial structures, aiding in the diagnosis of conditions such as:

- Fractures in the facial bones
- Tumors in the frontal lobe
- Conditions affecting the sinuses

Transverse Plane

The transverse plane, also known as the horizontal plane, divides the body into superior (upper) and inferior (lower) sections. This plane is particularly important for cross-sectional imaging.

Significance in Head Anatomy:

In the context of the head, the transverse plane is crucial for:

- Visualizing the brain's structures, such as the cerebrum, cerebellum, and brainstem
- Assessing the relationship between various cranial nerves and their exit points from the skull
- Identifying pathologies involving the base of the skull

Imaging modalities such as CT and MRI scans frequently utilize the transverse plane to provide comprehensive cross-sectional views of the head, enhancing the diagnostic process for conditions like:

- Intracranial hemorrhages
- Brain tumors
- Hydrocephalus

Applications in Clinical Practice

The understanding of planes of the head anatomy has several applications in clinical practice, ranging from diagnostics to surgical interventions.

Diagnostic Imaging

In modern medicine, imaging techniques have evolved to provide detailed visualizations of anatomical structures. The orientations of the sagittal, coronal, and transverse planes are essential for interpreting these images correctly.

- MRI: Utilizes all three planes to provide detailed images of soft tissues, particularly useful for assessing brain abnormalities.
- CT Scans: Often used in emergency settings, CT scans can provide quick cross-sectional images of the head to diagnose traumatic injuries, strokes, and tumors.

Surgical Interventions

Understanding the planes of head anatomy is crucial for surgical procedures, particularly in neurosurgery and maxillofacial surgery.

- Neurosurgery: Surgeons must navigate through specific planes to access the brain while minimizing damage to surrounding tissues. Knowledge of the transverse and coronal planes helps in planning craniotomies.
- Maxillofacial Surgery: In procedures involving the jaw, cheek, and facial structures, surgeons rely on the anatomical planes to ensure precision and symmetry in reconstructive surgeries.

Educational Purposes

Medical students and professionals often use anatomical planes as a foundation for learning anatomy. By understanding these planes, students can:

- Develop a spatial understanding of anatomical relationships.
- Communicate effectively about structures and their functions.
- Apply this knowledge in clinical assessments and procedures.

Conclusion

The planes of head anatomy are integral to the study and practice of medicine. They provide a framework for understanding the spatial relationships among various structures, which is crucial for diagnosis, treatment, and surgical interventions. A solid grasp of these anatomical planes enhances the ability of medical professionals to communicate effectively, interpret diagnostic images accurately, and perform complex procedures with precision. As medical technology advances, the importance of these anatomical concepts will continue to evolve, underpinning the future of head and neck medicine.

Frequently Asked Questions

What are the main anatomical planes of the head?

The main anatomical planes of the head include the sagittal plane, coronal plane, transverse plane, and oblique plane.

How does the sagittal plane divide the head?

The sagittal plane divides the head into left and right halves, running vertically from front to back.

What is the significance of the coronal plane in head anatomy?

The coronal plane divides the head into anterior (front) and posterior (back) sections, important for understanding facial symmetry and cranial structures.

What structures are typically assessed in the transverse plane of the head?

The transverse plane is used to assess structures like the brain, cranial nerves, and major blood vessels, providing a cross-sectional view.

How can understanding planes of the head aid in medical imaging?

Understanding the planes of the head is crucial for interpreting medical imaging techniques like CT and MRI, as they provide context for the orientation of structures.

What clinical applications are associated with the oblique plane in head anatomy?

The oblique plane is often used in imaging to view structures that are not well represented in standard planes, such as certain tumors or vascular malformations.

How do the planes of the head relate to surgical approaches?

Surgeons use the anatomical planes of the head to plan and execute procedures, ensuring minimal disruption to important structures and optimizing access.

Why is it important to understand the anatomical planes in dental practice?

In dental practice, understanding the anatomical planes helps in procedures like extractions, implants, and orthodontics, where precise orientation is crucial for success.

Find other PDF article:

<https://soc.up.edu.ph/15-clip/pdf?ID=Wqg58-6052&title=corporate-finance-the-core-berk-demarzo.pdf>

Planes Of The Head Anatomy

Aircraft database - corrections and additions

May 11, 2013 · The NATO AWACS planes are wrong in your database. NATO1, NATO6 & NATO7 have the correct callsign NATO01, NATO06 & NATO07

Aircraft database - corrections and additions

May 11, 2013 · The NATO AWACS planes are wrong in your database. NATO1, NATO6 & NATO7 have the correct ...

Explore the planes of the head anatomy in detail. Understand their significance and functions in medical studies. Learn more to enhance your knowledge today!

[Back to Home](#)