
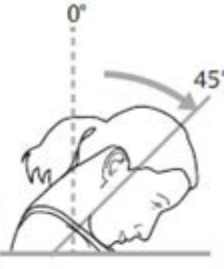

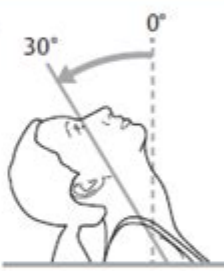
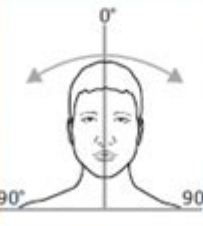
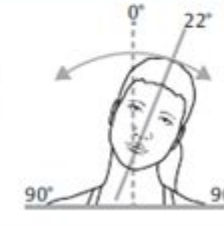
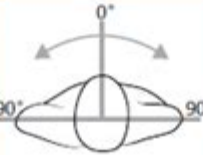
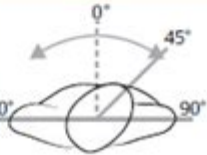


Neck Assessment Normal Findings

Normal Range of Movement		
Range of movement	Neutral position	Example
Flexion This could be measured in 0–90 degrees from the neutral position. Norm = about 38 degrees Or, it could be measured crudely in terms of how many centimeters (or inches) the subject's chin is from their sternum.		This person has about 45 degrees of flexion. Their chin is less than 1 cm from their sternum. They would appear to have a greater degree of cervical flexion than most people. 
Extension This could be measured in 0–90 degrees from the neutral position. Norm = about 38 degrees Or, it could be measured crudely in terms of how many centimeters (or inches) the subject's chin is from their sternum.		This person has about 30 degrees of extension. Their chin is about 22.5 cm from their chest. This appears to be slightly less than a normal range. 
Lateral flexion This could be measured in 0–90 degrees from the neutral position. Norm = about 43 degrees Or, you could measure crudely how far the client's ear is from their shoulder.		In this example, our subject has about 22 degrees of left lateral flexion, less than the norm. 
Rotation This could be measured in 0–90 degrees from the neutral position. Norm = about 45 degrees		

Neck assessment normal findings are a crucial aspect of physical examinations, particularly in clinical settings. The neck is a vital area of the body that houses essential structures, including the cervical spine, major blood vessels, nerves, and various glands. A thorough understanding of normal findings during a neck assessment can aid healthcare professionals in identifying abnormalities that may indicate underlying health issues.

Importance of Neck Assessment

Neck assessment is an integral part of a complete physical examination. It provides valuable insights into a patient's overall health and can help detect various conditions. Some key reasons for neck assessment include:

- Evaluation of cervical spine stability and mobility

- Assessment of the thyroid gland and other lymphatic structures
- Identification of vascular conditions
- Detection of tumors or other growths

Understanding normal findings is critical for healthcare providers to differentiate between healthy and pathological conditions.

Components of Neck Assessment

A comprehensive neck assessment typically includes the following components:

Visual Inspection

The first step in assessing the neck is visual inspection. Clinicians should look for any abnormalities, such as:

1. Swelling or enlargement of the thyroid gland (goiter)
2. Asymmetry in the neck or surrounding structures
3. Skin changes, such as rashes or lesions
4. Visible masses or lumps

Normal findings during visual inspection include a symmetrical neck with no swelling, lesions, or discoloration.

Palpation of Neck Structures

Palpation is essential for assessing the various anatomical structures in the neck. Key areas to palpate include:

- The cervical lymph nodes
- The thyroid gland
- The trachea

- The carotid arteries

Normal findings during palpation include:

- Cervical Lymph Nodes: Nodes should be non-tender, mobile, and less than 1 cm in size. They should not be hard or fixed to underlying tissues.
- Thyroid Gland: The gland should be smooth, symmetrical, and non-tender. It should move freely during swallowing, with no palpable nodules.
- Trachea: The trachea should be midline, and palpation should reveal no deviations or masses.
- Carotid Arteries: Pulsation should be strong and regular, with no bruits audible upon auscultation.

Range of Motion Assessment

Assessing the range of motion (ROM) of the neck is crucial for identifying any restrictions or pain. Normal neck ROM includes:

- Flexion: Ability to bend the neck forward, bringing the chin to the chest.
- Extension: Ability to tilt the head backward.
- Lateral Flexion: Ability to tilt the head toward each shoulder.
- Rotation: Ability to turn the head side to side.

Normal findings for neck ROM include smooth, pain-free movements in all directions, with no crepitus or stiffness.

Neurological Assessment

A neurological assessment of the neck involves evaluating sensory and motor functions related to cervical nerves. This assessment includes:

- Testing deep tendon reflexes (e.g., biceps reflex at C5, triceps reflex at C7)
- Assessing sensation in the upper extremities (C5 to T1 dermatomes)
- Evaluating the strength of shoulder shrug (accessory nerve, CN XI) and arm movements

Normal findings in neurological assessment include:

- Intact reflexes without hyperreflexia or hyporeflexia.
- Full sensation in the upper extremities without deficits.
- Normal muscle strength, with the ability to perform shoulder shrugs and arm movements without difficulty.

Vascular Assessment

The neck assessment also includes evaluating the vascular system, particularly the carotid arteries. Key aspects of the vascular assessment include:

Auscultation of Carotid Arteries

Listening for bruits over the carotid arteries can help identify potential vascular issues.

Normal findings for vascular assessment include:

- Absence of bruits upon auscultation.
- Symmetrical pulse strength in both carotid arteries.

Pulsation Assessment

Pulsation of the carotid arteries should be strong and regular, with no evidence of distension or abnormal waves.

Common Findings in Different Age Groups

Neck assessment findings may vary based on age. Understanding these variations is essential for accurate clinical evaluations.

Normal Findings in Pediatric Patients

In children, normal neck assessment findings typically include:

- Smaller size of cervical lymph nodes, which may be palpable but should be soft and non-tender.
- Normal range of motion, with no signs of stiffness or pain.

It is not uncommon for pediatric patients to have transient enlargement of lymph nodes during infections, which is typically benign.

Normal Findings in Adults

In adults, normal findings during neck assessment generally include:

- Well-defined cervical lymph nodes, which are typically not palpable unless there is an underlying infection or inflammation.
- The thyroid gland is often not palpable unless enlarged.
- Full range of motion without discomfort or limitation.

Normal Findings in Geriatric Patients

In older adults, the following normal findings may be observed:

- Slightly enlarged cervical lymph nodes may be present but should still be non-tender and mobile.
- Thyroid gland may become fibrotic, and nodules may be present; however, they should be evaluated further if there are concerns.
- Range of motion may decrease slightly due to age-related changes, but movements should remain smooth and without pain.

Conclusion

The neck assessment is a critical component of a comprehensive physical examination that provides valuable insights into a patient's health status. Normal findings during neck assessment include symmetrical structures, non-tender lymph nodes, a smooth thyroid gland, and full range of motion. Understanding these normal findings allows healthcare professionals to identify potential abnormalities early, ensuring timely intervention and improved patient outcomes. As clinicians conduct neck assessments across various patient populations, keeping these normal findings in mind will facilitate accurate diagnosis and effective management.

Frequently Asked Questions

What are the key normal findings when assessing the neck during a physical examination?

Key normal findings include a symmetrical neck with no visible masses or swelling, full range of motion without pain, and no tenderness upon palpation.

How can you assess the carotid arteries during a neck assessment?

You can assess the carotid arteries by palpating them one at a time, ensuring the pulse is strong and regular, and then listening for bruits using a stethoscope.

What does a normal range of motion in the neck entail?

A normal range of motion includes the ability to flex, extend, rotate, and laterally bend the neck without discomfort or restriction.

What is the significance of checking for lymph nodes during a neck assessment?

Checking for lymph nodes helps identify any enlargement or tenderness, which may indicate infection or other medical conditions, thus serving as an important part of the assessment.

What are the signs of a normal thyroid gland upon neck assessment?

A normal thyroid gland is not palpable, has no visible enlargement or nodules, and the patient should not experience any discomfort during palpation.

How do you determine if the trachea is midline during a neck assessment?

To determine if the trachea is midline, visually inspect and palpate the area above the suprasternal notch; it should be centrally located without deviation to either side.

Find other PDF article:

<https://soc.up.edu.ph/58-view/files?docid=WOF46-9835&title=the-bollinger-connections.pdf>

Neck Assessment Normal Findings

Cartiglio - WordReference Forums

Sep 30, 2008 · Qual'è la traduzione in inglese della parola italiana "cartiglio"? Per cartiglio intendo lo spazio rettangolare nelle mappe e nei disegni tecnici, normalmente in basso a destra, ...

[to keep the boot on the neck - WordReference Forums](#)

Dec 19, 2010 · Just because some don't find government redistribution acceptable, does not mean that they want corporations and/or the "wealthy" to place their boot on the neck ...

to get someone by the neck - WordReference Forums

Jan 28, 2011 · In the Spanish section, someone said that to get someone by the neck means to frighten someone which makes sense in most google hits. However, I first encountered this ...

back neck buggy - WordReference Forums

Aug 16, 2010 · hello! I am translation a mail order clothing catalogue and cannot find the French term for "back neck buggy" I'm not quite sure what it is, but it's on the back of t-shirts and polo ...

do/make experiment - WordReference Forums

Apr 3, 2011 · For number 2, one correction would be 'experiment with the bar in front of the neck'. Can I say, " Although I suggested that you hold the bar at the back of the neck there's no ...

'Would that the Roman people had but one neck!'

Jul 10, 2010 · 'Would that the Roman people had but one neck!' said the cruel emperor Caligula. 'Utinam populus Romanus sed (autem) unam cervicem haberet!' inquiebat Caligula imperator ...

beauty of a woman's neck - WordReference Forums

Oct 3, 2012 · Hi, Wordreference members. What is the best description you usually use to refer to a woman of a beautiful neck: - Her neck is as long as a giraffe's . - Her neck is as long as a ...

kink in the neck - WordReference Forums

Oct 25, 2008 · hola amigos, como se dice, "a kink" como un dolor en el cuello o la espalda? quiero decir que "I fell asleep and woke up with a kink in my neck" gracias!!

do the necessary vs. do the needful. - WordReference Forums

Aug 14, 2016 · I would like to know the difference or similarity between Do the necessary and do the needful. Leave it to me - I'll do the necessary. I couldn't find any example regarding "do ...

hung out or hanged out - WordReference Forums

Feb 12, 2011 · Hello, A question puzzled me today that: Should we write He often hung out with me those days or He often hanged out with me those days? Thank you.

Cartiglio - WordReference Forums

Sep 30, 2008 · Qual'è la traduzione in inglese della parola italiana "cartiglio"? Per cartiglio intendo lo spazio rettangolare nelle mappe e nei disegni tecnici, normalmente in basso a destra, contenente data, legenda, scala e altre informazioni.

to keep the boot on the neck - WordReference Forums

Dec 19, 2010 · Just because some don't find government redistribution acceptable, does not mean that they want corporations and/or the "wealthy" to place their boot on the neck vulnerable groups, like Obama suggests is the job of government to keep the boot on the neck of corporations or the wealthy such as BP or those who make more that \$250K/yr.

to get someone by the neck - WordReference Forums

Jan 28, 2011 · In the Spanish section, someone said that to get someone by the neck means to frighten someone which makes sense in most google hits. However, I first encountered this verbal phrase/idiom??/metaphor in a John Grisham novel where the meaning was probably a different one. In that context, a...

back neck buggy - WordReference Forums

Aug 16, 2010 · hello! I am translation a mail order clothing catalogue and cannot find the French term for "back neck buggy" I'm not quite sure what it is, but it's on the back of t-shirts and polo shirts by the collar. Can anyone help? Thanks.

do/make experiment - WordReference Forums

Apr 3, 2011 · For number 2, one correction would be 'experiment with the bar in front of the neck'. Can I say, " Although I suggested that you hold the bar at the back of the neck there's no reason why you shouldn't do some experiments with the bar held in front of the neck." ? Does the new sentence sound correct to native English speakers?

'Would that the Roman people had but one neck!'

Jul 10, 2010 · 'Would that the Roman people had but one neck!' said the cruel emperor Caligula. 'Utinam populus Romanus sed (autem) unam cervicem haberet!' inquiebat Caligula imperator crudelis.

beauty of a woman's neck - WordReference Forums

Oct 3, 2012 · Hi, Wordreference members. What is the best description you usually use to refer to a woman of a beautiful neck: - Her neck is as long as a giraffe's . - Her neck is as long as a bottleneck. - Her neck is as slender as a axe rod. Thanks in advance.

kink in the neck - WordReference Forums

Oct 25, 2008 · hola amigos, como se dice, "a kink" como un dolor en el cuello o la espalda? quiero decir que "I fell asleep and woke up with a kink in my neck" gracias!!

do the necessary vs. do the needful. - WordReference Forums

Aug 14, 2016 · I would like to know the difference or similarity between Do the necessary and do the needful. Leave it to me – I'll do the necessary. I couldn't find any example regarding "do the needful". However I've heard some local people using ...

hung out or hanged out - WordReference Forums

Feb 12, 2011 · Hello, A question puzzled me today that: Should we write He often hung out with me those days or He often hanged out with me those days? Thank you.

Discover the key normal findings in neck assessment to enhance your clinical skills. Learn more about effective techniques and essential indicators today!

[Back to Home](#)