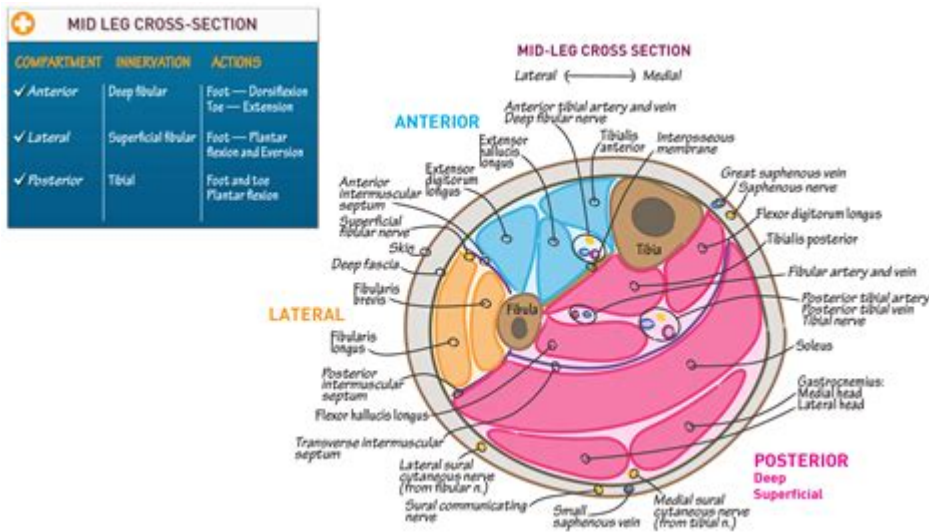


Lower Leg Cross Section Anatomy



Lower leg cross section anatomy is a fascinating subject that dives into the intricate structure of one of the most crucial parts of the human body. The lower leg, or the region between the knee and the ankle, consists of various tissues, including muscles, bones, nerves, and blood vessels. Understanding the anatomy of the lower leg through cross-sectional views is essential for diagnosing injuries, understanding functional biomechanics, and conducting surgical interventions. This article will explore the anatomy of the lower leg in a comprehensive manner, focusing on its structural components, their functions, and clinical relevance.

Overview of the Lower Leg Anatomy

The lower leg primarily consists of two long bones, the tibia and fibula, surrounded by muscles, tendons, ligaments, and neurovascular structures. The anatomy can be divided into several layers, each serving distinct functions.

The Bones

1. **Tibia:** The tibia, or shinbone, is the larger and stronger of the two bones in the lower leg. It supports the majority of the body's weight and is essential for locomotion.

- **Features:**
- **Medial malleolus:** The bony prominence on the inner side of the ankle.
- **Tibial tuberosity:** A prominent bump where the patellar ligament attaches.

2. **Fibula:** The fibula is the thinner bone located parallel to the tibia. While it bears less weight, it provides stability to the ankle and serves as an attachment site for muscles.

- Features:
- Lateral malleolus: The bony prominence on the outer side of the ankle.
- Proximal and distal ends: Important for muscle attachments.

The Muscles

The lower leg houses several muscle groups, which can be categorized into anterior, lateral, and posterior compartments.

1. Anterior Compartment:

- Muscles:
- Tibialis anterior: Responsible for dorsiflexion of the foot.
- Extensor hallucis longus: Extends the big toe.
- Extensor digitorum longus: Extends the other toes.
- Function: These muscles primarily facilitate foot dorsiflexion and toe extension.

2. Lateral Compartment:

- Muscles:
- Fibularis (peroneus) longus: Eversion of the foot and plantar flexion.
- Fibularis (peroneus) brevis: Assists in foot eversion.
- Function: These muscles stabilize the ankle during walking and running.

3. Posterior Compartment:

- Muscles:
- Gastrocnemius: The main calf muscle; involved in plantar flexion and knee flexion.
- Soleus: Works with the gastrocnemius for plantar flexion.
- Tibialis posterior: Supports the arch of the foot and aids in plantar flexion.
- Function: This compartment is crucial for actions like walking, running, and jumping.

Nerves of the Lower Leg

The lower leg is innervated by several important nerves that provide motor and sensory functions.

Major Nerves

1. Tibial Nerve: A branch of the sciatic nerve, it innervates the muscles of the posterior compartment and provides sensation to the plantar aspect of the foot.
2. Common Fibular Nerve: This nerve branches into the superficial and deep fibular nerves.

- Superficial Fibular Nerve: Innervates the lateral compartment muscles and provides sensation to the dorsum of the foot.
- Deep Fibular Nerve: Innervates the anterior compartment muscles and provides sensation between the first and second toes.

Blood Supply

The vascularization of the lower leg is crucial for delivering oxygen and nutrients to the tissues and facilitating waste removal. The primary blood supply comes from branches of the popliteal artery.

Main Arteries

1. Anterior Tibial Artery: Supplies the anterior compartment and continues as the dorsalis pedis artery at the ankle.
2. Posterior Tibial Artery: Supplies the posterior compartment and gives rise to the fibular artery, which supplies the lateral compartment.

Cross-Sectional Anatomy

Understanding the lower leg's cross-sectional anatomy is important for medical professionals in various fields, including orthopedics, physical therapy, and sports medicine.

Cross-Sectional Views

1. At the Mid-Shin Level:
 - The cross-section reveals the tibia centrally located with the fibula laterally positioned.
 - The anterior compartment muscles (tibialis anterior, extensor hallucis longus, extensor digitorum longus) are visible anteriorly.
 - The posterior compartment muscles (gastrocnemius, soleus) are positioned posteriorly.
 - Neurovascular structures, including the anterior tibial artery and deep fibular nerve, are present.
2. At the Ankle Level:
 - The cross-section shows the tibia and fibula with their respective malleoli.
 - Muscles from the anterior compartment are less prominent, with the presence of tendons transitioning into the foot.
 - The posterior compartment's tendons (including the Achilles tendon) are visible, providing essential function for plantar flexion.

Clinical Relevance

Understanding lower leg cross-section anatomy is vital for diagnosing and treating various conditions:

1. **Fractures:** Knowledge of the bone structure helps in identifying specific types of fractures and their management.
2. **Tendon Injuries:** Conditions such as Achilles tendonitis necessitate an understanding of muscle and tendon anatomy for rehabilitation.
3. **Compartment Syndrome:** An understanding of compartment anatomy is crucial for recognizing this potentially serious condition that can lead to muscle and nerve damage.
4. **Surgical Procedures:** Surgeons performing procedures like tendon repair or orthopedic surgeries must have a thorough understanding of the anatomical layout.

Conclusion

The anatomy of the lower leg, particularly through cross-sectional views, is a complex and essential field of study. The interplay between bones, muscles, nerves, and blood vessels plays a crucial role in mobility and overall function. A comprehensive understanding of this anatomy not only aids in the diagnosis and treatment of various medical conditions but also enhances the knowledge required for successful surgical interventions and rehabilitation strategies. As research and technology continue to evolve, further insights into lower leg anatomy will undoubtedly improve clinical practices and patient outcomes.

Frequently Asked Questions

What are the major bones found in the lower leg cross section?

The major bones in the lower leg cross section are the tibia and fibula.

Which muscles are primarily located in the lower leg?

The primary muscles in the lower leg include the gastrocnemius, soleus, tibialis anterior, and peroneal muscles.

What is the significance of the lower leg cross

section in medical imaging?

The lower leg cross section is significant in medical imaging as it helps in diagnosing fractures, muscle injuries, and vascular conditions.

How does the anatomy of the lower leg differ between athletes and non-athletes?

Athletes often have more developed muscles and tendons in the lower leg, which can lead to differences in cross-sectional area and strength compared to non-athletes.

What are the common vascular structures found in the lower leg cross section?

Common vascular structures include the anterior tibial artery, posterior tibial artery, and the peroneal artery.

How can understanding lower leg cross section anatomy aid in physical therapy?

Understanding lower leg cross section anatomy can aid in physical therapy by allowing therapists to target specific muscles and structures for rehabilitation and recovery.

Find other PDF article:

<https://soc.up.edu.ph/32-blog/pdf?docid=jlX00-3009&title=iep-writing-goals-examples.pdf>

Lower Leg Cross Section Anatomy

Magic: The Gathering | Official site for MTG news, sets, and events

The official source for news and information on Magic: The Gathering, the world's premier trading card game, and MTG Arena.

Latest MTG Sets & Products | Magic: The Gathering

The latest Magic: The Gathering card sets and products are now available to browse.

What Is MTG | Magic: The Gathering

Whether you're sitting at the kitchen table, playing online, or battling in a high-stakes competition, there's a place for you in the world of Magic: The Gathering.

MTG News, Announcements, and Podcasts - Magic: The Gathering

The official source for Magic: The Gathering news, announcements, podcasts, guest writers, and articles, directly from the people who develop Magic.

How to Play | Magic: The Gathering

Learn how to play Magic: The Gathering with rules and an introduction to the game!

SHOP - Magic: the Gathering

Explore the latest Magic: The Gathering products with ease! Discover and shop the newest sets, commander decks, play boosters, collector boosters, and more.

MTG Product Guide - Magic: The Gathering

Whether you're new to Magic: The Gathering or you've been building decks for years, use the guide below to find epic Magic products. You'll also be able to learn about Rares, special ...

Prerelease | Magic: The Gathering

Your store's schedule is a click away. Register early! Don't miss your chance to be the first to play the latest Magic set.

Magic: The Gathering Arena

Magic: The Gathering Arena puts the original CCG at your fingertips. Build a deck to play with friends or challenge the AI to master your strategy!

Secret Lair: The Sonic Superdrop - MAGIC: THE GATHERING

Jun 27, 2025 · Seven brand-new cards bring Sonic , Shadow , Dr. Eggman , and the crew to Magic: The Gathering for the first time. From the speed of Sonic to the nefarious chaos of Dr. ...

asian-girl-masturbation videos - XVIDEOS.COM

1080p POV - Asian stepdaughter puts on a masturbation show 11 min Girls of HEL - 13k Views -

'playboy masturbation' Search - XNXX.COM

Playboy Bunny with Big Tits has an Incredible Orgasm!

'playboy playmates masturbating' Search - XVIDEOS.COM

Hardcore activity with filthy Japanese porn. 6,360 playboy playmates masturbating FREE videos found on XVIDEOS for this search.

'playboy model solo masturbation' Search - XVIDEOS.COM

50,581 playboy model solo masturbation FREE videos found on XVIDEOS for this search.

'Asian solo playmate' Search - XVIDEOS.COM

Hot naked Japanese mummy in spectacular stockings, Nana Nakamura, leaves her super-naughty screwing playmate to seek out even more intense hardcore action - spectacular Asian ...

Playmate Masturbation Porn Videos | Pornhub.com

No other sex tube is more popular and features more Playmate Masturbation scenes than Pornhub! Browse through our impressive selection of porn videos in HD quality on any device ...

Hot Asian Masturbation Porn Videos | Pornhub.com

Browse through our impressive selection of porn videos in HD quality on any device you own.

Asian Playmates

Asian Playmates - the charming oriental Playboy Playmates, Playboy Centerfolds, and Playboy models of Asian descent from China, Japan, Philippines, and Thailand

asian-masturbation videos - XVIDEOS.COM

Hot Asian teacher masterclass: Blowjobs, Fucking, and Creampies (with pussy masturbation ASMR sound!) Uncensored Hentai. 4 min Compilations3D - 8 min POVAV - 3.1k Views - 81 ...

[Playboy Masturbate Porn Videos | Pornhub.com](#)

Browse through our impressive selection of porn videos in HD quality on any device you own.

Explore the intricacies of lower leg cross section anatomy. Discover how muscle

[Back to Home](#)