Human Anatomy Posterior View

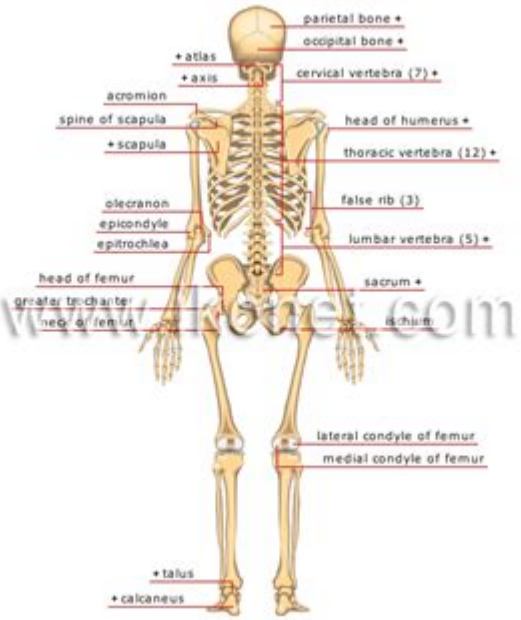

Human anatomy posterior view is an essential aspect of understanding how the body is structured and functions. The posterior view, or the back side of the human body, provides crucial insights into various anatomical features that are essential for both medical professionals and students of anatomy. This article will explore the major components of the human anatomy as seen from the posterior perspective, detailing the various systems, structures, and their significance.

Overview of the Human Body in Posterior View

The human body can be divided into several major regions when viewed from the posterior. These include the head, neck, trunk, and limbs. Each of these regions contains specific anatomical structures that serve vital functions. The posterior view allows us to observe how these systems interact and support overall health.

Regions of the Body

1. Cranial Region: The back of the skull, known as the occipital region, includes notable landmarks:
- Occipital bone
- Mastoid process of the temporal bone
- Nuchal lines for muscle attachment

2. Cervical Region: The back of the neck comprises:
- Cervical vertebrae (C1-C7)
- Nuchal ligament, which supports the head
- Trapezius muscle, which is responsible for moving the shoulder blades

3. Thoracic Region: The posterior thorax includes:
- Thoracic vertebrae (T1-T12)
- Ribs and their articulations with the vertebrae
- The scapula, or shoulder blade, which plays a crucial role in arm movement

4. Lumbar Region: The lower back consists of:
- Lumbar vertebrae (L1-L5)
- The erector spinae muscle group that supports posture

5. Pelvic Region: Posteriorly, the pelvis includes:
- Sacrum and coccyx
- Ilium, ischium, and pubis bones

6. Limbs: The posterior view of the limbs highlights:
- The gluteal region, including the gluteus maximus, medius, and minimus muscles
- The back of the thighs (hamstrings)
- The calves (gastrocnemius and soleus muscles)

Musculoskeletal System in Posterior View

Understanding the musculoskeletal system is crucial for appreciating human anatomy from the posterior view. This system comprises bones and muscles that provide structure, support, and movement.

Key Bones in the Posterior View

- Cervical Vertebrae: Allow for head movement and support the skull.
- Thoracic Vertebrae: Provide attachment points for the ribs and protect the thoracic cavity.
- Lumbar Vertebrae: Support the lower back and are crucial for movement and lifting.
- Sacrum and Coccyx: Form the posterior part of the pelvis and provide stability.

Major Muscles in the Posterior View

- Trapezius: Located in the upper back, responsible for moving the shoulder blades.
- Latissimus Dorsi: A large muscle in the lower back that aids in arm movement.
- Erector Spinae: A group of muscles that maintain posture and extend the spine.
- Gluteal Muscles: Essential for hip extension and stabilization during movement.

Nervous System in Posterior View

The nervous system, particularly the spinal cord and peripheral nerves, plays a critical role in body function. From the posterior view, we can observe how these structures are organized.

Spinal Cord and Nerves

- The spinal cord runs through the vertebral canal formed by the vertebrae.
- Spinal nerves exit the vertebrae at each level, branching out to innervate the limbs and trunk.
- The posterior aspect of the vertebrae protects the spinal cord, while intervertebral foramina allow nerves to exit.

Circulatory System in Posterior View

The circulatory system includes the heart, blood vessels, and associated structures. Viewing this system from the posterior aspect reveals several important features.

Major Blood Vessels

- Aorta: The largest artery that runs downward through the thorax and abdomen.
- Superior and Inferior Vena Cava: Large veins that return deoxygenated blood to the heart.
- Pulmonary Veins: Carry oxygenated blood from the lungs back to the heart.

Significance of Posterior Circulation

- The posterior circulation, supplied by the vertebral arteries, is critical for brain function.
- The basilar artery, formed by the fusion of the vertebral arteries, supplies blood to the brainstem and cerebellum.

Respiratory System in Posterior View

The respiratory system is essential for gas exchange, and the posterior view allows us to observe key structures involved in respiration.

Key Structures

- Lungs: The posterior surface of the lungs can be observed, including the lower lobes.
- Diaphragm: Although mainly viewed laterally, the diaphragm’s posterior attachment plays a role in breathing.
- Bronchi: The bifurcation of the trachea into the primary bronchi can be inferred from the posterior view.

Integumentary System in Posterior View

The integumentary system, which includes the skin, hair, nails, and glands, is vital for protection and sensory perception.

Skin Layers and Features

- Epidermis: The outer layer that protects underlying tissues.
- Dermis: Contains blood vessels, nerves, and connective tissue, providing elasticity and strength.
- Subcutaneous Layer: Composed of fat and connective tissue, it insulates the body and provides cushioning.

Common Posterior Skin Features

- Scapular Region: The skin overlying the scapula is often examined for muscle tension.
- Lumbar Region: Common site for skin conditions and injuries.
- Gluteal Region: Important for assessing posture and muscle development.

Clinical Applications of Understanding the Posterior View

Understanding human anatomy from the posterior view is not only academic but has real-world applications in clinical settings.

Physical Examination

- Medical professionals assess posture, muscle symmetry, and alignment.
- Identifying abnormalities or injuries in the back and limbs.

Rehabilitation and Therapy

- Knowledge of the posterior anatomy aids in designing rehabilitation programs.
- Targeting specific muscles and structures for recovery after injury.

Surgical Considerations

- Surgeons must understand posterior anatomy for procedures involving the spine, kidneys, and other structures.

Conclusion

In summary, the human anatomy posterior view is a rich field of study encompassing various systems and structures that are crucial for understanding human health and function. From the musculoskeletal framework to the complex interplay of the nervous and circulatory systems, each component plays an integral role. A thorough understanding of these structures not only enhances medical education but also informs clinical practices, ensuring better patient care and rehabilitation. The posterior view remains a vital perspective in both anatomical study and practical application in medicine.

Frequently Asked Questions

What structures are most prominently visible in a posterior view of the human body?

In a posterior view, prominent structures include the back muscles like the trapezius and latissimus dorsi, the spine, the gluteal muscles, and the back of the head.

How does the posterior view differ from the anterior view in human anatomy?

The posterior view shows the structures at the back of the body, including the spine and back muscles, while the anterior view highlights the front structures such as the chest and abdominal muscles.

What are the key bones visible in the posterior view of the human skeleton?

Key bones include the vertebral column (spine), scapulae (shoulder blades), and the posterior aspects of the skull and pelvis.

What role do the muscles visible in the posterior view play in human movement?

The muscles visible in the posterior view, such as the gluteal muscles and the muscles of the back, are crucial for posture, stability, and various movements like bending and twisting.

How can the posterior view aid in diagnosing medical conditions?

The posterior view can help identify asymmetries, posture abnormalities, and muscular imbalances, which can be indicators of conditions like scoliosis or muscular dystrophy.

What anatomical landmarks are used to identify regions in

the posterior view?

Key anatomical landmarks include the spinous processes of the vertebrae, the iliac crests, and the borders of the scapulae.

Why is understanding the posterior view important for physical therapy?

Understanding the posterior view allows physical therapists to assess posture, muscle strength, and flexibility, guiding rehabilitation programs effectively.

What imaging techniques can be used to study the posterior anatomy of the human body?

Imaging techniques such as MRI, X-rays, and CT scans can be used to study the posterior anatomy, providing detailed views of bones, muscles, and soft tissues.

What common injuries might be visible in the posterior view during a physical examination?

Common injuries that may be visible include muscle strains, ligament tears, and postural deformities like kyphosis or lordosis.

How does the posterior view assist in surgical procedures?

The posterior view is essential for planning surgeries on the spine, back muscles, and other structures, ensuring accurate incisions and interventions.

[Human Anatomy Posterior View]()

□□□□□□Please verify the CAPTCHA before proceed□□□□
□□□□□□□□□□□□□□□□□□□□□□Please verify the CAPTCHA before proceed□□□□□□□…

□□□□□□□□□□□□□□ms? - □□
□□□□□□□□□□□□□□□□□□□□□□220-240□□□□□□□□□□□□□□□150□□□□□□□□□□□□□□□□□□□□□□□□□□□□□□□□□□□□□□□167□□□□□□□ …

[Human□humans□□□□□□□□□□□ - □□]()
Human□humans□□□□□□□□□□□□ [□□] [□□] □□□□□□□□□□□□□□□□□□□□□□□□human□□□□□humans□ Human□□□□□□□□□□□□□□□□□□□□□□…

英语*person*，*people*，*human being*，*man*，*human*都有什么区 …

person 人，通常指一个人，没有persons这种用法。eg: she’s an interesting person. people 人们，集体名词。there are so many people travelling here. people有复数形式peoples，指民族 …

*CURSOR*软件，注册、*sign in* 问题？ - 知乎

CURSOR从软件点击sign in后无法打开网页，刷新无数次才能打开，打开后输入邮箱后，又出现Can‘t verify t…

*Mankind, Human, Man,Human-being*有何异同*?* - 知乎

human: a human being, especially a person as distinguished from an animal or (in science fiction) an alien human-being: a man, woman, or child of the species Homo sapiens (智人), …

如何知道一个期刊是不是**sci**？ **-** 知乎

欢迎大家持续关注InVisor学术科研！喜欢记得 点赞收藏转发！双击屏幕解锁快捷功能～ 如果大家对于「SCI/SSCI期刊论文发表」「SCOPUS 、CPCI/EI会议论文发表」「名校科研助理申请」 …

*stackoverflow*提问时人工验证失败怎么办？大家现在能正常提问 …

stackoverflow提问时人工验证失败怎么办？大家现在能正常提问吗？

本人14岁，反应速度平均192ms，这个反应是不是太慢了？想玩 …

目前在上网课谢邀 专业的关于人类反应时间的文章在知乎上很多，我这里简单的摘取部分。 @以宁致远 正常人反应速度在300毫秒左右.30岁以后会有所下降.运动员经过特定练习,对特定刺 …

Steam验证后总是出现会您对 CAPTCHA 的响应似乎无效。请在下 …

登录时忘记账号或密码，提示 APTCHA 的响应似乎无效，请在下方重新验证您不是机器人按以下步骤，亲测有效。在电脑上操作会受浏览器和加速器的限制，建议直接手机操作，简单迅速 1 …

提交表单显示*Please verify the CAPTCHA before proceed*怎么办？

本人因为旅游需要打印电子签证，但是提交后显示Please verify the CAPTCHA before proceed，换了好几个浏…

正常人的反应速度大概是多少ms? - 知乎

正常人的反应速度直接从网站测得的结果大多是220-240毫秒，去除点击鼠标的时间通常为150毫秒（去除由手指下落速度产生的时间影响），少数人可以达到网站直接数值167毫秒，而值得注 …

Human和**humans**的在句中的用法是什么？ **-** 知乎

Human和humans的在句中的用法是什么？［图片］［图片］疑问在上面图二的两个例句中，人类的表述都用了human的复数形式humans。Human作为集体名词，单数的时候就已经表达了复数…

英语*person*，*people*，*human being*，*man*，*human*都有什么区 …

person 人，通常指一个人，没有persons这种用法。eg: she’s an interesting person. people 人们，集体名词。there are so many people travelling here. people有复数形式peoples，指民族 …

CURSOR软件，注册、sign in 问题？ - 知乎

CURSOR从软件点击sign in后无法打开网页，刷新无数次才能打开，打开后输入邮箱后，又出现Can‘t verify t…

*Mankind, Human, Man,Human-being*有何异同*?* - 知乎

human: a human being, especially a person as distinguished from an animal or (in science fiction) an alien human-being: a man, woman, or child of the species Homo sapiens (智人), …

如何知道一个期刊是不是**sci**？ **-** 知乎

欢迎大家持续关注InVisor学术科研！喜欢记得 点赞收藏转发！双击屏幕解锁快捷功能～ 如果大家对于「SCI/SSCI期刊论文发表」「SCOPUS 、CPCI/EI会议论文发表」「名校科研助理申请」 …

stackoverflow提问时人工验证失败怎么办？大家现在能正常提问 **...**
stackoverflow提问时人工验证失败怎么办？大家现在能正常提问吗？

本人**14**岁，反应速度平均**192ms**，这个反应是不是太慢了？想玩 **...**
目前在上网课谢邀 专业的关于人类反应时间的文章在知乎上很多，我这里简单的摘取部分。 @以宁致远 正常人反应速度在300毫秒左右.30岁以后会有所下降.运动员经过特定练习,对特定刺 …

*Steam*验证后总是出现会您对 *CAPTCHA* 的响应似乎无效。请在下 …
登录时忘记账号或密码，提示 APTCHA 的响应似乎无效，请在下方重新验证您不是机器人按以下步骤，亲测有效。在电脑上操作会受浏览器和加速器的限制，建议直接手机操作，简单迅速 1 …

Explore the intricacies of human anatomy from the posterior view. Discover how muscles

Back to Home