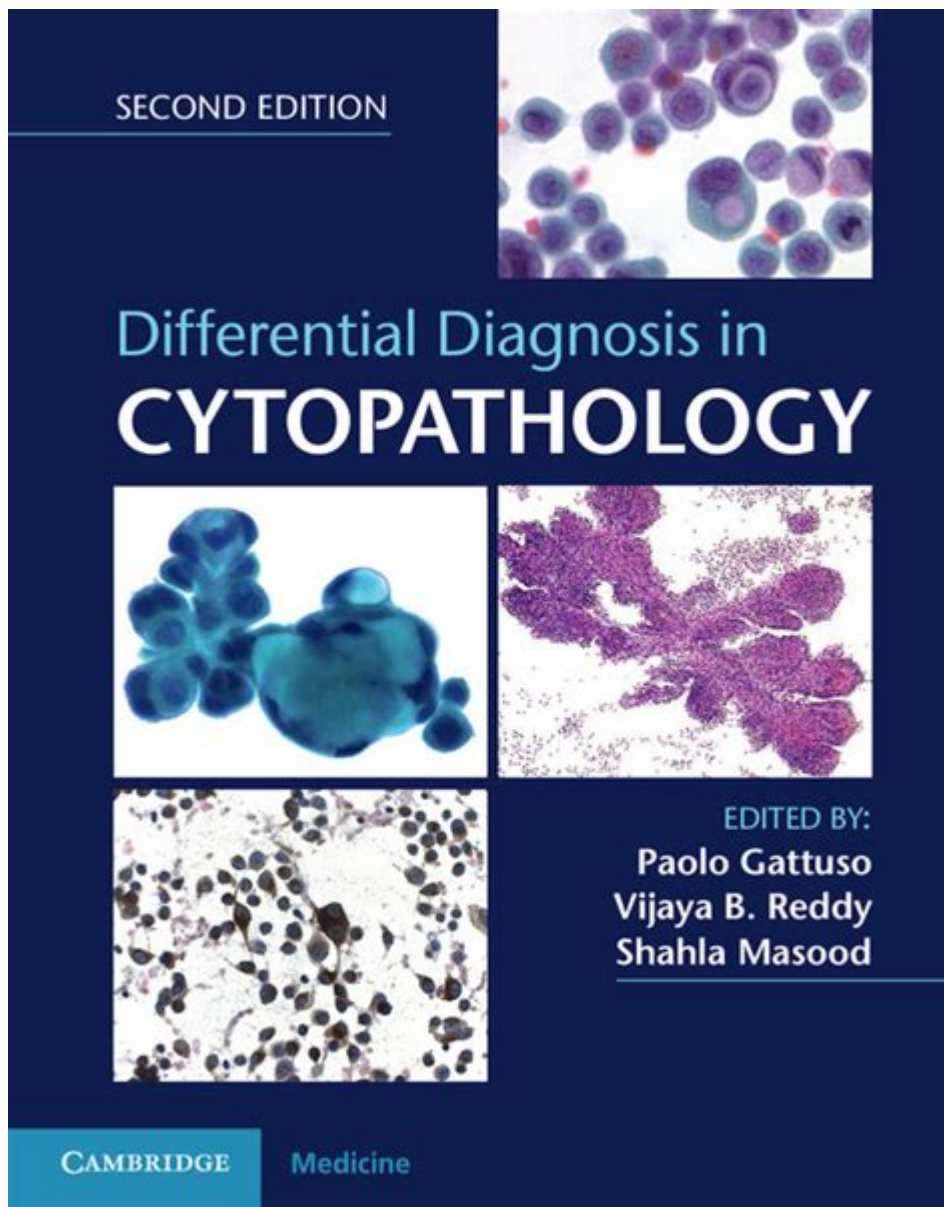


Differential Diagnosis In Cytopathology



Differential diagnosis in cytopathology is a critical process that involves distinguishing between different diseases or conditions based on cellular characteristics observed in cytology specimens. This branch of pathology focuses on the microscopic examination of cells to identify abnormalities that may indicate various pathological states, including infections, benign lesions, and malignancies. The accurate interpretation of cytological findings is essential for guiding clinical management and treatment decisions. Given the sheer diversity of possible diagnoses, a systematic approach to differential diagnosis is paramount.

Understanding Cytopathology

Cytopathology is a subspecialty of pathology that studies cells from various body sites to

diagnose diseases. Cytologists use various techniques, including fine needle aspiration (FNA), exfoliative cytology, and liquid-based cytology, to obtain samples. The key objectives of cytopathology include identifying:

- Malignant tumors
- Pre-malignant lesions
- Benign conditions
- Inflammatory processes

The primary advantage of cytopathology is its minimally invasive nature, which allows for rapid diagnosis and reduced patient morbidity. However, the challenge lies in the potential for overlapping cellular features among different conditions, necessitating a robust differential diagnosis approach.

The Differential Diagnosis Process

Differential diagnosis in cytopathology involves several steps, including obtaining clinical history, selecting appropriate specimens, performing microscopic examination, and correlating findings with clinical and radiological data.

1. Clinical History and Presentation

Understanding the patient's clinical background is crucial for guiding the differential diagnosis. Important factors to consider include:

- Age and gender of the patient
- Symptoms and duration
- History of smoking or exposure to carcinogens
- Previous medical history, including prior malignancies
- Family history of cancer
- Any recent infections or inflammatory conditions

These elements help to narrow down the list of potential diagnoses when interpreting cellular abnormalities.

2. Specimen Collection Techniques

The method of specimen collection can significantly influence the cytological findings. Common techniques include:

- Fine Needle Aspiration (FNA): Often used for palpable masses in the thyroid, breast, lymph nodes, and other organs.
- Exfoliative Cytology: Obtaining cells from body cavities or surfaces, such as Pap smears for cervical screening or bronchial washings for lung lesions.
- Liquid-Based Cytology (LBC): A technique that involves collecting cells in a liquid medium,

which helps preserve cellular morphology.

Each technique has its own limitations and advantages, impacting the quality and interpretability of the samples.

3. Microscopic Examination

Once the specimens are prepared, cytologists perform a thorough microscopic examination, assessing cellular architecture, nuclear characteristics, and the presence of any atypical features. Key factors evaluated during this process include:

- Cellularity: The number of cells present in the specimen.
- Cell arrangement: Patterns of cell organization (e.g., clusters, sheets, single cells).
- Nuclear features: Size, shape, chromatin pattern, and nucleoli.
- Cytoplasmic characteristics: Color, texture, and presence of abnormal inclusions.

These features can help distinguish between benign and malignant processes and identify specific types of tumors.

Common Conditions in Differential Diagnosis

Cytopathology encompasses a wide range of diseases, and certain conditions frequently require differentiation. The following are some common conditions and their distinguishing features:

1. Neoplastic Conditions

- Carcinoma: Malignant epithelial tumors can often be classified based on their origin (e.g., squamous cell carcinoma, adenocarcinoma). Key features include:
 - High nuclear-to-cytoplasmic ratio
 - Atypical mitotic figures
 - Irregular nuclear contours
- Sarcoma: Malignant mesenchymal tumors are generally more challenging to diagnose cytologically due to their varied presentations. Features include:
 - Spindle-shaped cells
 - High cellularity
 - Pleomorphic nuclei
- Lymphoma: Malignancies of lymphoid tissue can present with a range of cytological features. Key considerations include:
 - Bimodal age distribution
 - Presence of atypical lymphoid cells
 - Background of necrosis or inflammatory cells

2. Benign Conditions

- Infections: Cytological evaluation can indicate infectious processes, such as:
 - Bacterial infections: Often show neutrophilic infiltration and necrotic debris.
 - Viral infections: Features may include koilocytic changes (e.g., HPV) or multinucleated giant cells (e.g., herpes simplex virus).
- Inflammation: Inflammatory conditions may present with a mixed cellular background, including:
 - Lymphocytes in chronic inflammation
 - Neutrophils in acute inflammation
 - Necrosis or granulation tissue in chronic cases
- Benign Neoplasms: Such as adenomas or fibromas, can often be identified by:
 - Well-defined cellular arrangements
 - Absence of significant atypia
 - Uniform nuclear features

Challenges in Differential Diagnosis

The differential diagnosis process in cytopathology is fraught with challenges, including:

- Overlap of Features: Many conditions share cytological characteristics, making it difficult to arrive at a definitive diagnosis based solely on cellular morphology.
- Limited Material: Some cytology specimens may be scant, leading to difficulties in interpretation.
- Technical Artifacts: Improper sample preparation or staining can create artifacts that may mimic pathological changes.

To mitigate these challenges, cytologists often employ ancillary techniques, such as immunocytochemistry, molecular diagnostics, and flow cytometry, to enhance diagnostic accuracy.

Conclusion

Differential diagnosis in cytopathology is a complex but essential process that requires a thorough understanding of cellular morphology, clinical context, and available diagnostic tools. By following a systematic approach that includes careful evaluation of clinical history, specimen collection techniques, and microscopic examination, cytologists can effectively differentiate between a wide variety of conditions. Despite the challenges inherent in this field, advancements in technology and ancillary diagnostic methods continue to improve the accuracy and reliability of cytopathological diagnoses, ultimately leading to better patient outcomes.

Frequently Asked Questions

What is the significance of differential diagnosis in cytopathology?

Differential diagnosis in cytopathology is crucial for accurately identifying the nature of a lesion or disease based on cellular characteristics. It helps in distinguishing between benign and malignant conditions, guiding treatment decisions and prognostic evaluations.

What are common challenges faced in differential diagnosis within cytopathology?

Common challenges include overlapping cytological features between benign and malignant cells, artifacts that may mimic disease, and the need for correlation with clinical and radiological findings to avoid misdiagnosis.

How do ancillary studies aid in differential diagnosis in cytopathology?

Ancillary studies, such as immunocytochemistry and molecular testing, provide additional information that can clarify ambiguous cytological findings by identifying specific markers or genetic mutations, thus enhancing diagnostic accuracy.

What role does clinical history play in cytopathology differential diagnosis?

Clinical history is essential in differential diagnosis as it provides context regarding patient symptoms, risk factors, and previous medical conditions, which can influence the interpretation of cytological findings and help narrow down potential diagnoses.

What are some typical cytological features used in differential diagnosis?

Typical cytological features include cell morphology, nuclear characteristics (such as size, shape, and chromatin pattern), cytoplasmic features, and the presence of specific cellular arrangements, all of which help in distinguishing between different disease entities.

Find other PDF article:

<https://soc.up.edu.ph/01-text/pdf?dataid=MRo41-7665&title=2023-49ers-training-camp.pdf>

[Differential Diagnosis In Cytopathology](#)

different "Different" may only be an adjective. It describes a lack of similarity. "Tom and Jim are different people." "Tom and Jim each purchased a different number of apples." ...

differentiateddifferential -

Sep 13, 2024 · differentiateddifferential 1. differentiateddifferential ...

"differential" ...
"pseudo-differential" ...

differentiation,differentiate,differential ...

2013-06-27 · TA differentiation,differentiate,differential ...

What is the difference between "different " and "differential ...

The noun form of 'differential' typically refers to differences between amounts of things. For this case, the differential is the different amount between Tom's apples and Jim's apples.

-
(the Bessel differential equation) ...

difference differential ... - HiNative
difference differe...2Hinitive" ...

"differential(n)" "difference (n)" | HiNative

differential(n)"Differential" "difference" "Difference" -
There are many differences ...

Đâu là sự khác biệt giữa "different " và "differential
Đồng nghĩa với different 'Different' may only be an adjective. It describes a lack of similarity. "Tom and Jim are different people." "Tom and Jim each purchased a different number of apples." ...

...
Satoshi Nawata Differential Geometry and Topology in Physics ...

"different " "differential " | HiNative

different "Different" may only be an adjective. It describes a lack of similarity. "Tom and Jim are different ...

differentiateddifferential -

Sep 13, 2024 · differentiateddifferential 1. differentiated ...

"differential" ...
"pseudo-differential" ...

differentiation,differentiate,di...

2013-06-27 · TA differentiation,differentiate,differential ...

What is the difference between "different " and "differential ...

The noun form of 'differential' typically refers to differences between amounts of things. For this case, the ...

Explore essential strategies for differential diagnosis in cytopathology. Enhance your diagnostic skills and accuracy. Learn more for expert insights and tips!

[Back to Home](#)