

Diagram Surface Foot Anatomy

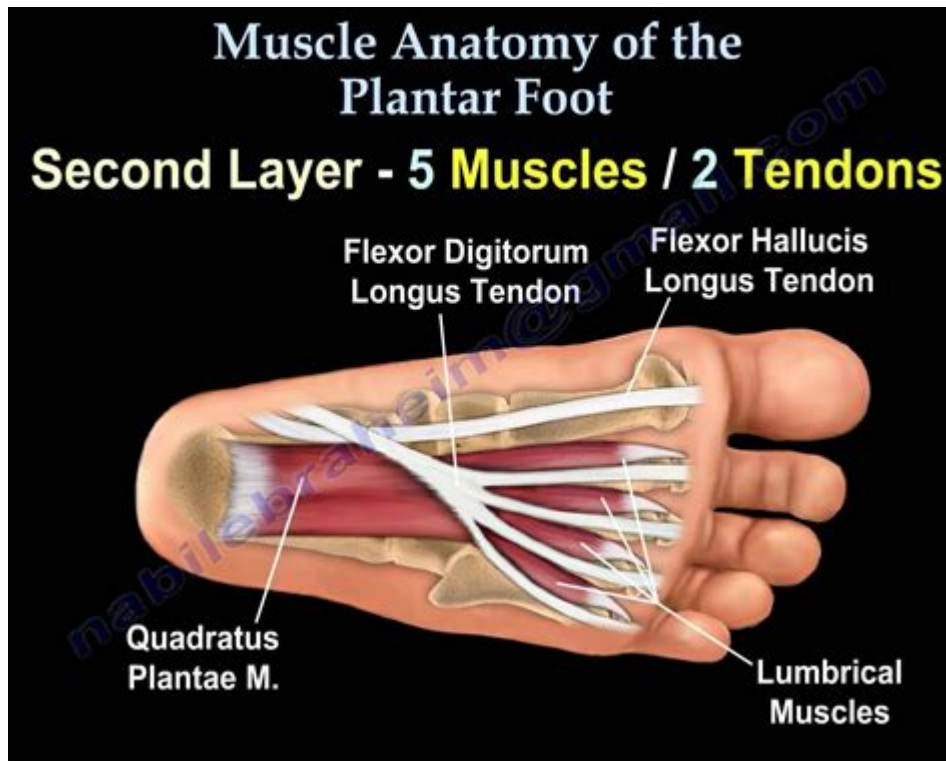


DIAGRAM SURFACE FOOT ANATOMY IS A CRITICAL ASPECT OF UNDERSTANDING HUMAN PHYSIOLOGY, PARTICULARLY FOR THOSE IN THE FIELDS OF MEDICINE, PHYSICAL THERAPY, AND SPORTS SCIENCE. THE FOOT IS A COMPLEX STRUCTURE THAT PLAYS AN ESSENTIAL ROLE IN MOBILITY AND WEIGHT-BEARING. THIS ARTICLE WILL PROVIDE AN IN-DEPTH ANALYSIS OF THE ANATOMY OF THE FOOT AS VIEWED FROM THE SURFACE, INCLUDING ITS BONES, MUSCLES, TENDONS, AND LIGAMENTS, WHILE ALSO DISCUSSING THE IMPORTANCE OF THIS KNOWLEDGE IN VARIOUS PRACTICAL APPLICATIONS.

OVERVIEW OF FOOT ANATOMY

THE HUMAN FOOT IS DIVIDED INTO THREE MAIN SECTIONS: THE FOREFOOT, MIDFOOT, AND HINDFOOT. EACH SECTION COMPRISES VARIOUS BONES, JOINTS, AND SOFT TISSUES THAT WORK TOGETHER TO PROVIDE STABILITY, MOBILITY, AND SUPPORT.

1. SECTIONS OF THE FOOT

- **FOREFOOT:** THIS SECTION INCLUDES THE TOES (PHALANXES) AND THE FIVE LONG BONES KNOWN AS METATARSALS. THE FOREFOOT IS RESPONSIBLE FOR THE PUSH-OFF PHASE OF WALKING AND IS CRUCIAL FOR BALANCE.
- **MIDFOOT:** COMPRISING THE FIVE TARSAL BONES (NAVICULAR, CUBOID, AND THREE CUNEIFORMS), THE MIDFOOT ACTS AS A FLEXIBLE ARCH THAT ABSORBS SHOCK AND HELPS WITH WEIGHT DISTRIBUTION.
- **HINDFOOT:** THE HINDFOOT CONSISTS OF THE TALUS AND CALCANEUS (HEEL BONE). THIS SECTION IS VITAL FOR THE FOOT'S OVERALL STRUCTURE AND SUPPORTS THE BODY'S WEIGHT DURING STANDING AND WALKING.

2. BONES OF THE FOOT

THE FOOT CONTAINS 26 BONES, WHICH CAN BE CATEGORIZED AS FOLLOWS:

1. PHALANGES: THERE ARE 14 PHALANGES IN THE TOES, WITH EACH TOE HAVING THREE (PROXIMAL, MIDDLE, AND DISTAL) EXCEPT FOR THE BIG TOE, WHICH HAS ONLY TWO.

2. METATARSALS: FIVE METATARSAL BONES CONNECT THE PHALANGES TO THE TARSAL BONES AND ARE NUMBERED ONE THROUGH FIVE, STARTING FROM THE MEDIAL (INNER) SIDE OF THE FOOT.

3. TARSALS: THE SEVEN TARSAL BONES INCLUDE:

- TALUS
- CALCANEUS
- NAVICULAR
- CUBOID
- MEDIAL CUNEIFORM
- INTERMEDIATE CUNEIFORM
- LATERAL CUNEIFORM

SOFT TISSUES OF THE FOOT

THE FOOT IS NOT JUST A SKELETAL STRUCTURE; IT IS ALSO COMPOSED OF VARIOUS SOFT TISSUES, INCLUDING MUSCLES, TENDONS, LIGAMENTS, AND FASCIA.

1. MUSCLES

THE MUSCLES OF THE FOOT CAN BE DIVIDED INTO TWO MAIN GROUPS: INTRINSIC AND EXTRINSIC.

- INTRINSIC MUSCLES: THESE MUSCLES ARE LOCATED WITHIN THE FOOT AND ARE RESPONSIBLE FOR FINE MOTOR CONTROL AND STABILITY. KEY INTRINSIC MUSCLES INCLUDE:

- ABDUCTOR HALLUCIS
- FLEXOR DIGITORUM BREVIS
- ABDUCTOR DIGITI MINIMI
- QUADRATUS PLANTAE
- LUMBRICALS
- INTEROSSEI MUSCLES

- EXTRINSIC MUSCLES: THESE MUSCLES ORIGINATE IN THE LOWER LEG AND CONTROL FOOT MOTION THROUGH THEIR TENDONS. MAJOR EXTRINSIC MUSCLES INCLUDE:

- TIBIALIS ANTERIOR
- GASTROCNEMIUS
- SOLEUS
- PERONEUS LONGUS AND BREVIS
- TIBIALIS POSTERIOR

2. TENDONS AND LIGAMENTS

TENDONS CONNECT MUSCLES TO BONES AND PLAY A CRUCIAL ROLE IN THE MOVEMENT OF THE FOOT. SOME NOTABLE TENDONS INCLUDE:

- ACHILLES TENDON: THIS IS THE LARGEST TENDON IN THE BODY, CONNECTING THE CALF MUSCLES TO THE CALCANEUS.

- **TIBIALIS ANTERIOR TENDON:** THIS TENDON HELPS IN DORSIFLEXION OF THE FOOT.

LIGAMENTS CONNECT BONES TO OTHER BONES AND PROVIDE STABILITY. IMPORTANT LIGAMENTS OF THE FOOT INCLUDE:

- **DELTOID LIGAMENT:** A LARGE LIGAMENT ON THE MEDIAL SIDE OF THE ANKLE THAT PROVIDES STABILITY DURING WEIGHT-BEARING ACTIVITIES.
- **LATERAL COLLATERAL LIGAMENTS:** THESE LIGAMENTS, WHICH INCLUDE THE ANTERIOR TALOFIBULAR, POSTERIOR TALOFIBULAR, AND CALCANEOFIBULAR LIGAMENTS, PROVIDE LATERAL STABILITY TO THE ANKLE.

FUNCTION OF THE FOOT ANATOMY

UNDERSTANDING THE DIAGRAM SURFACE FOOT ANATOMY IS VITAL FOR VARIOUS FUNCTIONS, INCLUDING:

1. WEIGHT BEARING

THE FOOT IS DESIGNED TO SUPPORT THE WEIGHT OF THE BODY. THE ARCHES OF THE FOOT—MEDIAL LONGITUDINAL, LATERAL LONGITUDINAL, AND TRANSVERSE—PLAY A CRUCIAL ROLE IN DISTRIBUTING THIS WEIGHT EVENLY AND ABSORBING SHOCK DURING ACTIVITIES LIKE WALKING, RUNNING, AND JUMPING.

2. MOBILITY

THE FOOT'S COMPLEX STRUCTURE ALLOWS FOR A WIDE RANGE OF MOTION. ITS FLEXIBILITY ENABLES ACTIONS SUCH AS:

- **DORSIFLEXION:** RAISING THE FOOT UPWARDS.
- **PLANTARFLEXION:** POINTING THE FOOT DOWNWARDS.
- **INVERSION:** TURNING THE SOLE OF THE FOOT INWARD.
- **EVERSION:** TURNING THE SOLE OF THE FOOT OUTWARD.

CLINICAL RELEVANCE OF FOOT ANATOMY

A THOROUGH UNDERSTANDING OF FOOT ANATOMY IS ESSENTIAL FOR DIAGNOSING AND TREATING VARIOUS CONDITIONS.

1. COMMON FOOT CONDITIONS

SOME CONDITIONS THAT MAY ARISE DUE TO ABNORMALITIES IN FOOT ANATOMY INCLUDE:

- **PLANTAR FASCIITIS:** INFLAMMATION OF THE PLANTAR FASCIA, CAUSING HEEL PAIN.
- **FLATFOOT:** A CONDITION WHERE THE ARCHES OF THE FOOT COLLAPSE, LEADING TO MISALIGNMENT.
- **ACHILLES TENDINITIS:** INFLAMMATION OF THE ACHILLES TENDON, OFTEN CAUSED BY OVERUSE.
- **BUNIONS:** A BONY BUMP THAT FORMS AT THE BASE OF THE BIG TOE, LEADING TO MISALIGNMENT.

2. IMPORTANCE IN REHABILITATION

FOR PHYSICAL THERAPISTS AND REHABILITATION SPECIALISTS, UNDERSTANDING THE DIAGRAM SURFACE FOOT ANATOMY IS CRUCIAL IN DESIGNING EFFECTIVE TREATMENT PLANS. KNOWLEDGE OF MUSCLE GROUPS, TENDONS, AND LIGAMENTS HELPS IN:

- CREATING TARGETED EXERCISES TO STRENGTHEN SPECIFIC AREAS OF THE FOOT.
- ASSESSING GAIT PATTERNS TO IDENTIFY ABNORMALITIES AND RECOMMEND CORRECTIVE MEASURES.
- PREVENTING INJURIES BY EDUCATING PATIENTS ON PROPER FOOTWEAR AND FOOT CARE.

CONCLUSION

THE DIAGRAM SURFACE FOOT ANATOMY PROVIDES A COMPREHENSIVE UNDERSTANDING OF THE FOOT'S STRUCTURE AND FUNCTION. WITH ITS INTRICATE INTERCONNECTIONS OF BONES, MUSCLES, TENDONS, AND LIGAMENTS, THE FOOT IS A MARVEL OF BIOLOGICAL ENGINEERING. THIS KNOWLEDGE IS INDISPENSABLE NOT ONLY FOR HEALTHCARE PROFESSIONALS BUT ALSO FOR ATHLETES, FITNESS ENTHUSIASTS, AND ANYONE INTERESTED IN MAINTAINING FOOT HEALTH. UNDERSTANDING THE ANATOMY OF THE FOOT CAN LEAD TO BETTER PREVENTION AND MANAGEMENT OF INJURIES, ENSURING THAT INDIVIDUALS CAN CONTINUE TO ENGAGE IN THEIR DAILY ACTIVITIES AND SPORTS WITHOUT DISCOMFORT.

FREQUENTLY ASKED QUESTIONS

WHAT ARE THE MAJOR BONES OF THE FOOT THAT SHOULD BE INCLUDED IN A SURFACE ANATOMY DIAGRAM?

THE MAJOR BONES INCLUDE THE CALCANEUS, TALUS, NAVICULAR, CUBOID, CUNEIFORMS (MEDIAL, INTERMEDIATE, LATERAL), METATARSALS, AND PHALANXES.

HOW CAN A DIAGRAM OF FOOT ANATOMY HELP IN DIAGNOSING COMMON FOOT AILMENTS?

A DIAGRAM CAN HELP VISUALIZE THE RELATIONSHIPS BETWEEN BONES, MUSCLES, AND LIGAMENTS, AIDING IN THE IDENTIFICATION OF ISSUES LIKE FRACTURES, PLANTAR FASCIITIS, AND TENDONITIS.

WHAT MUSCLES ARE TYPICALLY HIGHLIGHTED IN A FOOT ANATOMY SURFACE DIAGRAM?

KEY MUSCLES INCLUDE THE TIBIALIS ANTERIOR, GASTROCNEMIUS, SOLEUS, FLEXOR DIGITORUM LONGUS, AND THE INTRINSIC MUSCLES SUCH AS THE ABDUCTOR HALLUCIS AND FLEXOR DIGITI MINIMI.

WHAT LIGAMENTS ARE IMPORTANT TO INCLUDE IN A FOOT SURFACE ANATOMY DIAGRAM?

IMPORTANT LIGAMENTS ARE THE DELTOID LIGAMENT, ANTERIOR TALOFIBULAR LIGAMENT, CALCANEOFIBULAR LIGAMENT, AND THE PLANTAR FASCIA.

WHAT IS THE SIGNIFICANCE OF THE ARCHES IN FOOT ANATOMY DIAGRAMS?

THE ARCHES (MEDIAL, LATERAL, AND TRANSVERSE) PLAY A CRUCIAL ROLE IN WEIGHT DISTRIBUTION AND SHOCK ABSORPTION, AND THEIR INTEGRITY IS ESSENTIAL FOR OVERALL FOOT FUNCTION.

HOW DOES UNDERSTANDING FOOT SURFACE ANATOMY CONTRIBUTE TO ATHLETIC

PERFORMANCE?

KNOWLEDGE OF FOOT ANATOMY HELPS IN OPTIMIZING FOOTWEAR, IMPROVING BIOMECHANICS, AND PREVENTING INJURIES, ALL OF WHICH ENHANCE ATHLETIC PERFORMANCE.

WHAT ARE COMMON VARIATIONS IN FOOT ANATOMY THAT SHOULD BE NOTED IN SURFACE DIAGRAMS?





COMMON VARIATIONS INCLUDE FLAT FEET, HIGH ARCHES, AND VARIATIONS IN TOE ALIGNMENT, WHICH CAN IMPACT FUNCTION AND PREDISPOSE INDIVIDUALS TO CERTAIN INJURIES.

Find other PDF article:

<https://soc.up.edu.ph/36-tag/pdf?trackid=1eE25-0922&title=language-arts-worksheets-grade-5.pdf>

Diagram Surface Foot Anatomy

graph chart diagram form table

Aug 9, 2023 · Diagram  diagram  circuit diagram   ...

graph chart diagram form table

graph[]chart[]diagram[]form[]table[] [] [] Graph[] []graph
paper. Chart[] [] ...

chart diagram graph figure ...

chart: A chart is a diagram, picture, or graph which is intended to make information easier to understand. chart diagram picture graph ...

graph|chart|diagram| |

```
graph[]chart[]diagram[]1[]diagram[]chart[]graph[]
[]2[] ...
```

chart, diagram, graph, figure

Feb 10, 2025 · [Chart](#) [diagram](#) [graph](#) [figure](#) [1. Chart](#) [...](#)

<i>table</i>	<i>graph</i>	<i>diagram</i>	<i>chart</i>	<i>figure</i>					
--------------	--------------	----------------	--------------	---------------	--	--	--	--	--

3 diagram " " " " 4 chart + chart table, graph, diagram chart

□□□□□□□□□□□□□□ - □□

IT

schematic diagram

Aug 14, 2024 · ["schematic diagram"](#) ["ski:'mæɪtɪk 'daɪəgræm"](#) ...

