Deer Front Shoulder Anatomy

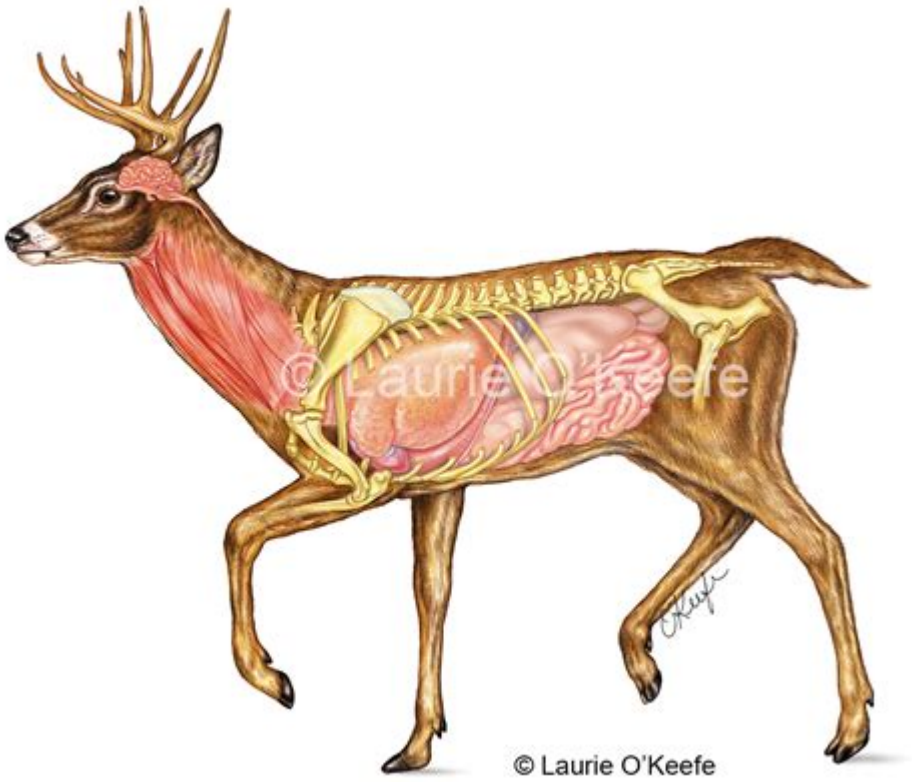

Deer front shoulder anatomy is a fascinating subject that plays a crucial role in understanding the overall physiology of these remarkable animals. The front shoulder of a deer is not merely a structural component; it is integral to their movement, feeding, and survival. In this article, we will delve into the intricate anatomy of the deer's front shoulder, exploring its bones, muscles, tendons, and their functions. This knowledge is invaluable for wildlife enthusiasts, hunters, and anyone interested in deer biology.

Overview of Deer Anatomy

Understanding deer front shoulder anatomy begins with a brief overview of the deer's skeletal structure. Deer, being part of the Cervidae family, possess a unique skeletal system adapted for their environment. Their anatomy is designed for agility, allowing them to traverse diverse terrains efficiently. The front shoulder is a key area that contributes to their locomotion and overall health.

The Skeletal Framework

The front shoulder of a deer consists of several critical bones that form a complex joint system. The primary bones involved are:

1. Scapula (Shoulder Blade):
- The scapula is a flat, triangular bone that connects the upper arm to the torso. It allows for a wide

range of motion in the forelimb.

2. Humerus:
- The humerus is the bone of the upper forelimb that runs from the shoulder to the elbow. It plays a vital role in the movement and stability of the front leg.

3. Radius and Ulna:
- These two bones make up the forearm. The radius is located on the lateral side, while the ulna is on the medial side. Together, they aid in the movement and positioning of the hoof.

4. Carpal Bones:
- These are the small bones that make up the wrist joint. They allow for flexibility and movement of the lower leg.

5. Metacarpals and Phalanges:
- The metacarpals are long bones in the hand region, while the phalanges are the bones of the toes (hooves). In deer, these structures are adapted for weight-bearing and locomotion.

Joint Structure and Function

The shoulder joint of a deer is a ball-and-socket joint formed by the articulation of the scapula and the humerus. This type of joint allows for a greater range of motion compared to other joint types, which is essential for a deer's agility and speed.

- Glenoid Cavity: A shallow socket in the scapula that accommodates the head of the humerus.
- Joint Capsule: A fibrous tissue that surrounds the joint, providing stability and containing synovial fluid for lubrication.
- Ligaments: Strong connective tissues that connect bones to other bones, providing support and limiting excessive movement.

The Muscular System of the Front Shoulder

Muscles in the deer's front shoulder are critical for movement and strength. They allow the deer to run, jump, and navigate through various terrains. The primary muscle groups include:

Major Muscle Groups

1. Supraspinatus:
- Located above the scapula, this muscle helps raise the front leg and is crucial for initial movement.

2. Infraspinatus:
- Found below the scapula, this muscle assists in the rotation of the humerus and stabilizes the shoulder joint.

3. Subscapularis:

- This muscle lies beneath the scapula and aids in the internal rotation of the humerus.

4. Deltoid:
- A large muscle covering the shoulder, it is involved in raising the forelimb and providing stability.

5. Biceps Brachii:
- This muscle is located on the front of the humerus and is responsible for flexing the forelimb.

6. Triceps Brachii:
- Located on the back of the humerus, it extends the forelimb and is crucial for powerful movements.

Supporting Structures

In addition to muscles, several other structures support the function of the front shoulder:

- Tendons: These connective tissues attach muscles to bones, allowing for movement.
- Ligaments: Besides connecting bones, some ligaments help stabilize muscles and joints during movement.
- Bursae: Fluid-filled sacs that reduce friction between bones and soft tissues, protecting the shoulder during movement.

Functional Importance of the Front Shoulder

The front shoulder anatomy of a deer is not only about structure but also about function. Understanding how this anatomical area works helps us appreciate the deer’s adaptations for survival.

Locomotion

The front shoulder plays a pivotal role in locomotion. Key points include:

- Running and Jumping: The range of motion in the shoulder joint allows deer to sprint and leap over obstacles effectively.
- Stability on Uneven Terrain: The muscular and skeletal structure provides the deer with the stability needed to navigate rocky or uneven ground.
- Power Generation: The triceps and biceps work together to propel the deer forward, generating the necessary power for quick movements.

Feeding and Grazing

The anatomy of the front shoulder also impacts how deer feed:

- Reaching for Food: The extensive movement range allows deer to stretch and reach vegetation that

may be out of grasp for other animals.
- Posture: The shoulder structure supports the deer’s ability to lower its head for grazing without compromising balance.

Health and Injuries

Understanding deer front shoulder anatomy also aids in recognizing potential health issues and injuries that may arise. Common concerns include:

- Shoulder Dislocation: Caused by falls or accidents, this can lead to loss of mobility and pain.
- Muscle Strains: Overexertion during fleeing or jumping can result in muscle strains, leading to limping or reluctance to move.
- Joint Issues: Conditions like arthritis can affect the shoulder joint, resulting in chronic pain and reduced mobility.

Signs of Injury

Deer exhibit several signs that may indicate shoulder injuries, including:

- Limping or Favoring One Leg: This could suggest pain or discomfort in the shoulder.
- Limited Range of Motion: Difficulty raising the leg or maintaining posture while grazing may indicate joint or muscle issues.
- Behavioral Changes: Increased aggression or withdrawal from social interactions can also signal injury or discomfort.

Conclusion

In conclusion, the deer front shoulder anatomy is a complex yet elegantly designed system that facilitates the deer’s lifestyle. From the skeletal structure to the muscular system, each component plays a vital role in enabling movement, feeding, and overall survival. A deeper understanding of this anatomy not only enhances appreciation for these graceful animals but also informs effective management and conservation efforts. Whether you are a wildlife enthusiast, hunter, or simply curious about deer, recognizing the significance of the front shoulder anatomy can enrich your knowledge and experiences with these remarkable creatures.

Frequently Asked Questions

What is the primary function of the front shoulder in deer anatomy?

The front shoulder in deer plays a crucial role in mobility, allowing for efficient movement and support for the weight of the body during activities such as running, jumping, and grazing.

How does the shoulder structure of deer differ from that of other mammals?

Deer have a unique shoulder structure that includes a flexible scapula, which allows for a greater range of motion and agility compared to many other mammals, helping them navigate through dense forests and evade predators.

What muscles are primarily involved in the movement of a deer's front shoulder?

Key muscles involved in the movement of a deer's front shoulder include the supraspinatus, infraspinatus, and biceps brachii, which work together to facilitate various actions such as running and lifting the front limbs.

How does the anatomy of a deer’s shoulder affect its foraging behavior?

The anatomy of a deer's shoulder allows for a wide range of motion, enabling deer to reach for food in various positions, whether it's grazing on the ground or browsing on higher vegetation.

What adaptations do deer have in their shoulder anatomy for survival in their habitat?

Deer have evolved a lightweight yet strong shoulder structure that enhances their speed and agility, which is essential for escaping predators in their natural habitats.

Can injuries to a deer’s front shoulder impact its overall health and mobility?

Yes, injuries to a deer's front shoulder can significantly affect its mobility and ability to forage, leading to potential long-term health issues if the deer is unable to move or feed properly.

Deer Front Shoulder Anatomy

梅花鹿的英文名，为什么叫sika deer，不叫meihua deer？ - 知乎
Jan 3, 2022 · 梅花鹿的英文名之所以叫“sika deer”，而不是“meihua deer”，主要是因为西方学者在命名这个物种时，依据的是日语中的称呼。 "Sika"是日语“シカ”的音译，这 …

为什么英语单词的deer鹿，是单复数同型，明明是可以按个数数出的…
Mar 17, 2016 · antelope 羚羊，bison 野牛，buffalo 水牛，crab 螃蟹，deer 鹿，fish 鱼，reindeer 驯鹿 这些动物在英国古代，英国人都是一群一群的去数的，词汇诞生时 …

英语单词「**deer**」是什么时候、如何从「泛指动物」变成「特指鹿」 **...**

Deer这个词在古英语中为deor，指“野生动物、野兽以及各种四足野兽”，在早期中古英语还可以指“蚂蚁、鱼”。可以说，在那个时候，这个词所指的动物范围非常广。这个词源自 ...

麋鹿到底是**elk** 还是 **peer David's deer**，哪个更准确一点**? -** 知乎

May 28, 2020 · Père David's deer才是正确的（注意大小写，还有Père中的前一个是è，不是e），peer David's deer是错误的！ 另外，也可以翻译成milu 、mi-deer—— ...

外贸提单**B/L、HB/L、MB/L**是什么？有何区别？ **-** 知乎

提单（Bill of Lading,B/L）是由船长或承运人或承运人的代理人签发，证明收到特定货物，允许将货物运至特定目的地并交付于收货人的凭证。 MB/L是MASTER ...

梅花鹿的英文名，为什么叫sika deer，不叫meihua deer？ - 知乎

Jan 3, 2022 · 梅花鹿的英文名之所以叫“sika deer”，而不是“meihua deer”，主要是因为西方学者在命名这个物种时，依据的是日语中的称呼。 "Sika"是日语“シカ”的音译，这个词在日本用于指代鹿。

为什么英语单词的**deer**鹿，是单复数同型，明明是可以按个数数出的？ **-** 知乎

Mar 17, 2016 · antelope 羚羊，bison 野牛，buffalo 水牛，crab 螃蟹，deer 鹿，fish 鱼，reindeer 驯鹿 这些动物在英国古代，英国人都是一群一群的去数的，词汇诞生时就是“集合名词”，后来单数也用同 ...

英语单词「*deer*」是什么时候、如何从「泛指动物」变成「特指鹿」的？ - 知乎

Deer这个词在古英语中为deor，指“野生动物、野兽以及各种四足野兽”，在早期中古英语还可以指“蚂蚁、鱼”。可以说，在那个时候，这个词所指的动物范围非常广。这个词源自原始日耳曼语*deuzam“动物”，– ...

麋鹿到底是*elk* 还是 *peer David's deer*，哪个更准确一点*?* - 知乎

May 28, 2020 · Père David's deer才是正确的（注意大小写，还有Père中的前一个是è，不是e），peer David's deer是错误的！ 另外，也可以翻译成milu 、mi-deer——音译是双向的，英文的有些词汇 ...

外贸提单*B/L、HB/L、MB/L*是什么？有何区别？ - 知乎

提单（Bill of Lading,B/L）是由船长或承运人或承运人的代理人签发，证明收到特定货物，允许将货物运至特定目的地并交付于收货人的凭证。 MB/L是MASTER B/L（MASTER BILL OF LOADING）是船东提 ...

Explore the intricate deer front shoulder anatomy

Back to Home