Ct Lumbar Spine Anatomy

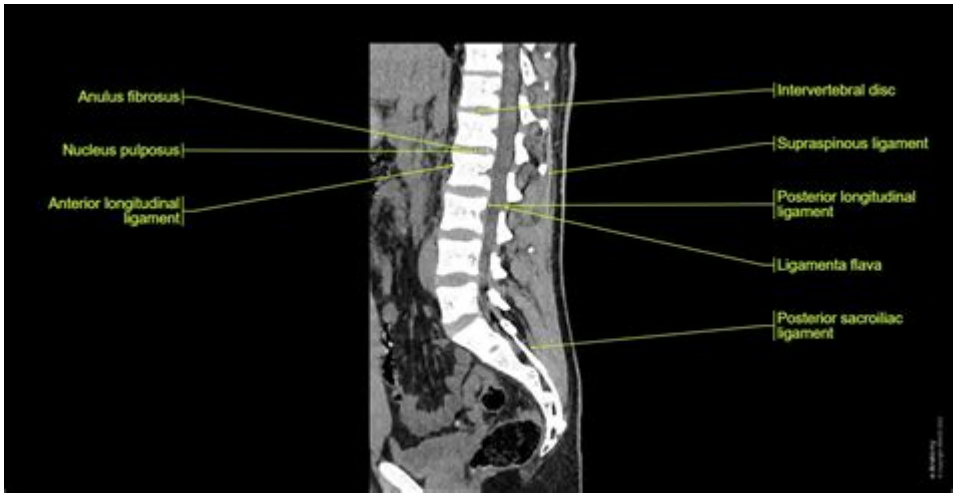

CT Lumbar Spine Anatomy

The lumbar spine, located in the lower back, is a critical component of the human skeletal system. It consists of five vertebrae (L1 to L5) that play a vital role in supporting the upper body, facilitating movement, and protecting the spinal cord and nerve roots that branch out from it. Understanding the anatomy of the lumbar spine is essential for diagnosing and treating various spinal disorders, especially when using advanced imaging techniques such as computed tomography (CT). This article delves into the intricate structure of the lumbar spine, its components, and the significance of CT imaging in evaluating lumbar spine conditions.

Basic Structure of the Lumbar Spine

The lumbar spine is characterized by its unique structure that provides flexibility and strength. The components of the lumbar spine include:

1. Vertebrae

The lumbar region comprises five individual vertebrae:

- L1 (First Lumbar Vertebra): This vertebra connects with the thoracic spine above and the second lumbar vertebra below. It is larger than the thoracic vertebrae, reflecting the load it bears.
- L2 (Second Lumbar Vertebra): Similar in structure to L1, L2 provides stability and acts as an anchor for the muscles and ligaments of the lower back.
- L3 (Third Lumbar Vertebra): Positioned at the midpoint of the lumbar spine, L3 is crucial for weight distribution and movement.

- L4 (Fourth Lumbar Vertebra): This vertebra is larger and thicker, designed to withstand significant loads during activities such as lifting and bending.
- L5 (Fifth Lumbar Vertebra): The largest of the lumbar vertebrae, L5 connects the lumbar spine to the sacrum, forming the lumbosacral junction.

2. Intervertebral Discs

Located between each pair of lumbar vertebrae, intervertebral discs serve as shock absorbers and allow for movement. Each disc consists of two main parts:

- Nucleus Pulposus: The gel-like center that provides cushioning.
- Annulus Fibrosus: The tough outer layer that encases the nucleus and provides structural support.

3. Spinal Canal and Nerve Roots

The spinal canal runs through the center of the vertebrae, housing the spinal cord and nerve roots. As the spinal cord transitions into the lumbar region, it tapers into a structure known as the conus medullaris. Below this point, the nerve roots extend downward, resembling a horse's tail, termed the cauda equina. Each nerve root exits the spinal canal through foramina located between adjacent vertebrae.

4. Ligaments and Muscles

The lumbar spine is stabilized by several ligaments and muscles:

- Ligaments: The anterior and posterior longitudinal ligaments run along the length of the spine, while the ligamentum flavum connects adjacent vertebrae.
- Muscles: The muscles surrounding the lumbar spine, including the erector spinae and multifidus, contribute to spinal stability and facilitate movement.

CT Imaging of the Lumbar Spine

Computed tomography (CT) is a powerful imaging modality that provides detailed cross-sectional images of the lumbar spine. It is particularly useful in identifying various conditions affecting the lumbar region.

1. Indications for CT Imaging

CT scans of the lumbar spine are commonly performed for several reasons, including:

- Assessment of Trauma: Evaluating fractures or dislocations following a traumatic injury.
- Degenerative Conditions: Diagnosing conditions like degenerative disc disease or spinal stenosis.
- Tumors and Infections: Identifying neoplasms or infections affecting the vertebral bodies and surrounding structures.
- Preoperative Planning: Providing detailed anatomy for surgeons before lumbar spine surgery.

2. Advantages of CT Imaging

CT imaging offers several advantages when evaluating the lumbar spine:

- High Resolution: CT scans provide excellent detail of the bone structures, making them superior for visualizing fractures or bony abnormalities.
- Rapid Acquisition: CT scans can be performed quickly, which is beneficial in emergency settings.
- 3D Reconstruction: Advanced CT techniques allow for three-dimensional reconstruction of the lumbar spine, aiding in surgical planning.

3. Limitations of CT Imaging

Despite its benefits, CT imaging has certain limitations:

- Radiation Exposure: CT scans involve exposure to ionizing radiation, which may be a concern for certain populations.
- Limited Soft Tissue Evaluation: While CT is excellent for visualizing bony structures, it is less effective for assessing soft tissue, such as the spinal cord, nerves, and intervertebral discs.

Common Pathologies of the Lumbar Spine

Several pathologies can affect the lumbar spine, many of which can be effectively evaluated using CT imaging.

1. Herniated Discs

A herniated disc occurs when the nucleus pulposus protrudes through the annulus fibrosus, potentially compressing adjacent nerve roots. CT imaging can help visualize the extent of the herniation and any resulting nerve root

compression.

2. Spinal Stenosis

Spinal stenosis refers to the narrowing of the spinal canal, which can lead to compression of the spinal cord and nerves. CT can reveal the degree of narrowing and the presence of osteophytes (bone spurs) contributing to the condition.

3. Spondylolisthesis

Spondylolisthesis is a condition in which one vertebra slips forward over another. CT imaging can help determine the degree of slippage and assess any associated changes in the spinal canal.

4. Osteoporosis and Fractures

Osteoporosis can lead to vertebral compression fractures, which are often visible on CT scans. Identifying these fractures is crucial for managing pain and preventing further injury.

Conclusion

The lumbar spine is a complex structure that plays a vital role in the overall function of the human body. Understanding its anatomy is essential for healthcare professionals involved in diagnosing and treating spinal conditions. CT imaging has revolutionized the way we evaluate lumbar spine disorders, providing detailed insights into bony structures and pathologies. By combining a thorough understanding of lumbar spine anatomy with advanced imaging techniques, clinicians can deliver more effective and targeted treatment options for patients suffering from various lumbar spine conditions. As research and technology continue to advance, our understanding and management of lumbar spine conditions will only improve, ultimately enhancing patient outcomes and quality of life.

Frequently Asked Questions

What are the main components of the lumbar spine

anatomy as seen on a CT scan?

The main components include the five lumbar vertebrae (L1-L5), intervertebral discs, lumbar spinal nerves, facet joints, and surrounding soft tissue structures.

How does CT imaging assist in diagnosing lumbar spine conditions?

CT imaging provides detailed cross-sectional images of the lumbar spine, allowing for the assessment of bone integrity, detection of fractures, evaluation of disc herniation, and identification of spinal stenosis.

What are common pathologies that can be identified in the lumbar spine using CT?

Common pathologies include herniated discs, degenerative disc disease, spinal stenosis, spondylolisthesis, and facet joint arthritis.

What is the significance of the lumbar spinal canal in CT lumbar spine anatomy?

The lumbar spinal canal houses the spinal cord and spinal nerves; its size and shape are critical for diagnosing conditions like spinal stenosis, which can compress these structures.

How do the anatomical landmarks of the lumbar spine differ in various age groups as seen on CT?

In younger individuals, lumbar vertebrae tend to be more hydrated and less degenerated, while in older adults, CT may show signs of degeneration, disc bulging, and osteophyte formation.

Find other PDF article:
https://soc.up.edu.ph/49-flash/Book?trackid=odX18-8417&title=psychology-in-everyday-life-ebook.pdf

Ct Lumbar Spine Anatomy

电缆桥架里的**MR、CT**是什么意思？？？？_百度知道

Dec 11, 2024 · CT代表槽式桥架，这是一种开放式金属结构，用于支持和引导电缆的路径，便于电缆的敷设和维护。例如，"CT 400X200"表示一种宽度为400毫米、高度为200毫米的槽式桥架，这种桥 ...

CT的成像原理是什么？ - 知乎

CT是计算机断层扫描显像（computed tomography）的简称，一般临床上说的CT，就是以X光为放射源所建立的断层图像，也就是X光CT，但事实上所有可以造成影像并用计算机建立断层图的系统，都可 ...

请问一下，有人知道ct三维成像中的矢状位、冠状位、轴位如何描 ...

嘚不嘚 照相的 2 人赞同了该回答 冠状位：把人体分为前后部分 矢状位：把人分为左右部分 轴位：把人分为上下部分 写报告的话，直接说看见什么，片子拿出去外面的大夫和病人可见不到ct三维 编辑于 ...

有大佬可以科普一下核磁共振和**CT**有什么区别吗？ - 知乎

Oct 20, 2020 · CT检查 很安静，磁共振检查 噪声大。专业角度的区别： CT 密度分辨力高，磁共振 软组织分辨力高。以胸部CT为例，理论上CT能分辨大于0.75mm以上的肺结节，而磁共振在肺部检查 ...

电缆敷设方式**CT、CE、WE、WC、CC**各表示什么？

Sep 22, 2023 · CT：电缆桥架敷设；CE：沿天棚顶敷设；WE：沿墙明敷；WC:沿墙暗敷设；CC：沿顶板暗敷设。以下是我收集的电气设计施工图中常用线路敷设方式

增强**CT**与增强**MRI**的区别，同样都是增强，这两个检查哪个更有诊 ...

Jan 30, 2025 · 增强CT与增强MRI虽然都通过注射对比剂提升影像的清晰度，但两者的技术原理、适用场景和诊断价值存在显著差异。 **无法简单判断哪种检查“更好”，其诊断价值的高低需根据具体疾病 ...

g、ct、lb、oz、gn、ozt、dwt是什么单位_百度知道

g、ct、lb、oz、gn、ozt、dwt都是质量单位。率属于不同的国家。 g（gram）是克的意思。ct （carat 或 karat）是克拉的意思。lb （pound）是磅的意思。oz （ounce）是盎司的意思。gn（grain） ...

CT、CE、WE、WC、CC是什么意思？_百度知道

Aug 12, 2024 · 1. 在电气安装图中，“CT”代表电缆桥架敷设，即电缆沿着桥架进行布线。 2. “CE”标识的是沿天棚顶敷设，意味着电缆在天棚的顶部进行敷设。 3. “WE”指的是沿墙明敷，即电缆在墙面明露 ...

电气图纸中的**CT、CE、WE、CC**是什么意思？_百度知道

Sep 15, 2024 · 电气图纸中的CT、CE、WE、CC分别表示电缆桥架敷设、沿天棚面或顶棚面敷设、沿墙明敷、暗敷设在顶棚内。 CT在电气图纸中主要有两种含义：在平面图上，CT表示电缆沿电缆桥架敷 ...

什么是薄层CT，和普通CT有区别吗？ - 知乎

Nov 15, 2022 · 作为在CT岗位操作了6年多的放射技师，经常都会收到临床关于薄层CT扫描的需求，现在来跟大家分享一下薄层CT是什么？与厚层CT有什么区别？

电缆桥架里的MR、CT是什么意思? ? ? ? _百度知道

Dec 11, 2024 · CT代表槽式桥架，这是一种开放式金属结构，用于支持和引导电缆的路径，便于电缆的敷设和维护。例如，"CT 400X200"表示一种宽度为400毫米、高度为200毫米的槽式桥架，这种桥 ...

*CT*的成像原理是什么？ - 知乎

CT是计算机断层扫描显像（computed tomography）的简称，一般临床上说的CT，就是以X光为放射源所建立的断层图像，也就是X光CT，但事实上所有可以造成影像并用计算机建立断层图的系统，都可 ...

请问一下，有人知道ct三维成像中的矢状位、冠状位、轴位如何描 ...

嘚不嘚 照相的 2 人赞同了该回答 冠状位：把人体分为前后部分 矢状位：把人分为左右部分 轴位：把人分为上下部分 写报告的话，直接说看见什么，片子拿出去外面的大夫和病人可见不到ct三维 编辑于 ...

有大佬可以科普一下核磁共振和**CT**有什么区别吗？ - 知乎

Oct 20, 2020 · CT检查 很安静，磁共振检查 噪声大。专业角度的区别： CT 密度分辨力高，磁共振 软组织分辨力高。以胸部CT为例，理论上CT能分辨大于0.75mm以上的肺结节，而磁共振在肺部检查 ...

电缆敷设方式CT、CE、WE、WC、CC各表示什么？

Sep 22, 2023 · CT: 电缆桥架敷设; CE: 沿天棚顶敷设; WE: 沿墙明敷; WC:沿墙暗敷设; CC: 沿顶板暗敷设。以下是我收集的电气设计施工图中常用线路敷设方式

增强**CT**与增强**MRI**的区别，同样都是增强，这两个检查哪个更有诊 **...**
Jan 30, 2025 · 增强CT与增强MRI虽然都通过注射对比剂提升影像的清晰度，但两者的技术原理、适用场景和诊断价值存在显著差异。 **无法简单判断哪种检查“更好”，其诊断价值的高低需根据具体疾病 ...

*g、ct、lb、oz、gn、ozt、dwt*是什么单位_百度知道
g、ct、lb、oz、gn、ozt、dwt都是质量单位。率属于不同的国家。 g（gram）是克的意思。 ct （carat 或 karat）是克拉的意思。 lb （pound）是磅的意思。 oz （ounce）是盎司的意思。 gn（grain） ...

CT、 CE、 WE、 WC、 CC是什么意思? **_**百度知道
Aug 12, 2024 · 1. 在电气安装图中，“CT”代表电缆桥架敷设，即电缆沿着桥架进行布线。 2. “CE”标识的是沿天棚顶敷设，意味着电缆在天棚的顶部进行敷设。 3. “WE”指的是沿墙明敷，即电缆在墙面明露 ...

电气图纸中的CT、 CE、 WE、 CC是什么意思? _百度知道
Sep 15, 2024 · 电气图纸中的CT、CE、WE、CC分别表示电缆桥架敷设、沿天棚面或顶棚面敷设、沿墙明敷、暗敷设在顶棚内。 CT在电气图纸中主要有两种含义：在平面图上，CT表示电缆沿电缆桥架敷 ...

什么是薄层**CT**，和普通**CT**有区别吗? **-** 知乎
Nov 15, 2022 · 作为在CT岗位操作了6年多的放射技师，经常都会收到临床关于薄层CT扫描的需求，现在来跟大家分享一下薄层CT是什么？与厚层CT有什么区别?

Explore the essential aspects of CT lumbar spine anatomy. Understand its structures and functions for better insights. Learn more about your spine health today!

Back to Home