Bones In The Wrist And Hand

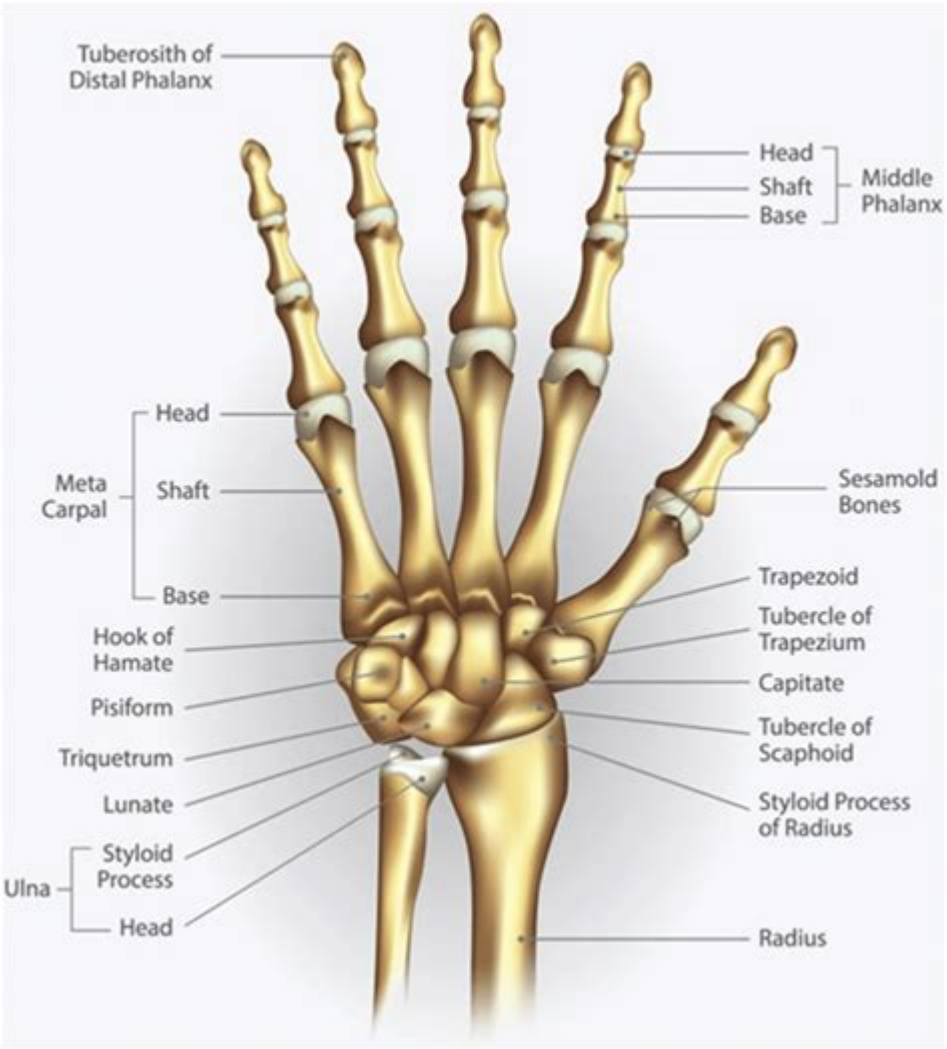

Bones in the wrist and hand play crucial roles in the overall functionality of the upper limb, enabling a wide range of movements and activities. The intricate structure of the wrist and hand consists of numerous bones that work together to provide both strength and dexterity. Understanding the anatomy of these bones is essential for anyone interested in fields such as medicine, sports science, or even art, where hand coordination is vital. This article will explore the various bones within the wrist and hand, their classifications, functions, and common injuries associated with them.

Overview of the Wrist and Hand Bones

The human wrist and hand comprise a complex arrangement of bones that can be classified into three main categories: carpal bones, metacarpal bones, and phalanges. Each category serves a unique purpose in facilitating movement and providing support.

1. Carpal Bones

The wrist includes eight small bones collectively known as the carpal bones. These bones are arranged in two rows, with four bones in each row. The carpal bones contribute significantly to the wrist's flexibility and strength, allowing for a wide range of motions.

Proximal Row:
- Scaphoid: Located on the thumb side of the wrist, it is the largest bone in the proximal row and often involved in wrist fractures.
- Lunate: Situated between the scaphoid and triquetrum, the lunate is crescent-shaped and plays a key role in wrist articulation.
- Triquetrum: Positioned next to the lunate, the triquetrum is important for enabling motion between the wrist and the forearm.
- Pisiform: This small, pea-shaped bone sits atop the triquetrum and serves primarily as a site for muscle attachment.

Distal Row:
- Trapezium: Located at the base of the thumb, this bone allows for the thumb's wide range of motion, including opposition.
- Trapezoid: Found next to the trapezium, this bone is the smallest of the distal row and helps stabilize the index finger.
- Capitate: The largest carpal bone, it sits centrally in the wrist and provides stability to the hand.
- Hamate: Recognizable by its hook-like projection, the hamate is located on the ulnar side of the wrist and serves as an attachment point for ligaments.

2. Metacarpal Bones

The hand contains five metacarpal bones, numbered one through five from the thumb to the little finger. These long bones connect the carpal bones of the wrist to the phalanges of the fingers.

- Metacarpal I: Supports the thumb and is crucial for opposition, allowing the thumb to touch the other fingers.
- Metacarpal II: Associated with the index finger, it is the longest of the metacarpals.
- Metacarpal III: Corresponds to the middle finger and is often the most robust metacarpal.
- Metacarpal IV: Links to the ring finger and is slightly shorter than the third.
- Metacarpal V: Attached to the little finger, it has a distinctive hook-like feature at its base.

Together, these metacarpal bones form the palm of the hand, providing structure and support for grasping and fine motor functions.

3. Phalanges

The fingers consist of 14 phalanges, which are categorized into three sections for each finger (proximal, middle, and distal) except for the thumb, which has only two (proximal and distal).

- Proximal Phalanges: The first segment of each finger, connecting to the metacarpals.
- Middle Phalanges: Present in the index, middle, ring, and little fingers but absent in the thumb.
- Distal Phalanges: The tip of each finger, where tactile sensation and fine manipulation occur.

Each phalanx is further divided into a base, shaft, and head, providing a suitable framework that enables intricate movements.

Functions of the Bones in the Wrist and Hand

The bones in the wrist and hand are designed to perform various functions, making them indispensable for everyday activities. Here are some of the key roles they play:

- Grasping and Holding: The combination of carpal, metacarpal, and phalangeal bones allows for a strong grip, enabling individuals to hold objects securely.
- Dexterity: The fine motor skills required for activities such as writing, playing musical instruments, and typing depend on the coordinated movements of these bones.
- Support and Stability: The carpal bones provide a stable base for the hand while allowing for a range of motions, including flexion, extension, and rotation.
- Shock Absorption: The arrangement of the wrist bones helps absorb impact forces during activities, reducing the risk of injury.

Common Injuries and Conditions

Despite their strength and resilience, the bones in the wrist and hand are susceptible to various injuries and conditions. Here are some of the most common issues:

1. Fractures

Fractures are among the most frequent injuries affecting the wrist and hand bones, often resulting from falls, sports injuries, or accidents.

- Scaphoid Fracture: Often occurs when a person falls onto an outstretched hand. It can lead to complications if not diagnosed and treated promptly.
- Colles' Fracture: A distal radius fracture typically occurring in older adults, often caused by falling on an outstretched hand.
- Metacarpal Fractures: Commonly known as "boxer’s fractures," these occur when the hand is used to punch an object.

2. Carpal Tunnel Syndrome

This condition results from pressure on the median nerve as it travels through the wrist, leading to symptoms such as tingling, numbness, and weakness in the hand. It often requires surgical intervention if conservative treatments fail.

3. Tendon Injuries

The wrist and hand are home to various tendons that can be injured through repetitive motions or trauma, leading to conditions like tendinitis or tendon ruptures.

Conclusion

Understanding the bones in the wrist and hand is essential for anyone looking to appreciate the complexity and functionality of the human body. The carpal, metacarpal, and phalangeal bones work in harmony to provide strength, flexibility, and dexterity, enabling individuals to perform a myriad of tasks, from simple daily activities to intricate skilled movements. Awareness of common injuries and conditions related to these bones can help individuals take proactive steps to protect their wrist and hand health, ensuring they can continue to engage in their favorite activities for years to come. Whether you are a medical professional, an athlete, or simply someone interested in anatomy, the bones of the wrist and hand are a fascinating and vital subject worth exploring.

Frequently Asked Questions

What are the main bones of the wrist?

The main bones of the wrist, known as carpal bones, include the scaphoid, lunate, triquetrum, pisiform, trapezium, trapezoid, capitate, and hamate.

How many bones are in the human hand?

The human hand consists of 27 bones: 8 carpal bones in the wrist, 5 metacarpal bones in the palm, and 14 phalanges in the fingers.

What is the function of the carpal bones?

The carpal bones provide flexibility and stability to the wrist, allowing for a wide range of motion and the ability to grip objects.

What common injuries affect the bones in the wrist and hand?

Common injuries include fractures (especially of the scaphoid), sprains, and repetitive strain injuries such as carpal tunnel syndrome.

How do wrist fractures typically occur?

Wrist fractures often occur due to falls onto an outstretched hand, sports injuries, or direct trauma.

What is carpal tunnel syndrome?

Carpal tunnel syndrome is a condition caused by compression of the median nerve as it travels through the wrist, leading to pain, numbness, and weakness in the hand.

What are the signs of a wrist fracture?

Signs of a wrist fracture include swelling, pain, bruising, and difficulty moving the wrist or hand.

How can I prevent wrist injuries?

Prevent wrist injuries by practicing proper ergonomics, using wrist supports during repetitive activities, and strengthening wrist muscles through exercises.

What is the significance of the scaphoid bone?

The scaphoid bone is significant because it is the most commonly fractured carpal bone, and its injury can lead to complications such as avascular necrosis if not treated properly.

Bones In The Wrist And Hand

美剧《识骨寻踪》（Bones)真有那么好看吗? 为啥能拍到第10季
尤其在第11季开始booth失踪，bones在尸骨间独自一个人拿着骨头，简直泪奔 2.每个人都是独立的个体，都有不一样的性格特征，也各有缺点和优点，是完整意义上的人，而不是一个故意美化 …

深度学习网络中backbone是什么意思? - 知乎
1.backbone: 翻译为主干网络的意思，既然说是主干网络，就代表其是网络的一部分，那么是哪部分呢? 翻译的很好，主干部分，哈哈哈哈，文字游戏了哈。这个主干网络大多时候指的是提取 …

如何评价育碧的《碧海黑帆 Skull & Bones》? - 知乎
而最近育碧居然也这么玩儿了！育碧新作《碧海黑帆》（Skull & Bones），就是以《刺客信条：黑旗》的海战部分作为蓝本，开发的 船新游戏。当年X博士玩黑旗，就是把它当做大航海时 …

如何评价骨头社（BONES）的动画? - 知乎
相比较现在的许多大厂，bones的产量是不高的，一般年产3~6部左右，这对于一个老牌动画制作公司而言是可以接受的。可如果你仔细研究过BD销量后就会发现其暴死几率是真的不小。

如何评价骨头社（BONES）的动画? - 知乎
BONES是1998年成立的新公司，是家管理型的公司，成名的时候还算是年轻的。制作过的作品不多，但是类型挺丰富的，什么风格都有。有很出名的，比如《钢炼》，比如《交响诗篇》。 …

识骨寻踪一到十季有哪几集让你印象最深? - 知乎
我特别喜欢第一季的第16集，看完惊呼，这集编剧真棒！一个片段：Bones让安吉拉去根据知情人描述画人的素描，安吉拉特别抵触，她觉得Harold overmeyer是个异类，却又没有办法只能硬 …

识骨寻踪中**Bones**和**Both**谁爱对方更多? - 知乎
你指的是什么方面的付出？精神方面，bones自己一直努力克服着自己的心理压力，第二季的萨利那么好，她依然没敢跨出那一步，第五季布斯表白了，她依然困于内心选择拒绝，直到第六季 …

美剧《识骨寻踪》（**Bones)**真有那么好看吗? 为啥能拍到第**10**季
本剧最大bug：凶手的投胎速度 华盛顿特区 绝对被诅咒了！按剧情密度计算：平均每1.5天出现一具尸体 每周至少1个连环杀手上线 每季必有1个实验室成员被绑架（建议 杰斐逊学院在招生简 …

句中的**make no bones about**是什么意思**? -** 知乎
What the devil does a mentor do when the sinner make no bones about confessing his sin?

如何看待**B**站**up**主欠债调音狮作品《电棍：**bones**》被反复下架?
纯客观来说，审核的原因只有一个，那就是内容。为什么《zood》在B站就不会下架，而是限流，那到了《奥利奥利安》这里就是下架? 其实B站暗中给很多东西都限流，最经典的就是电棍 …

美剧《识骨寻踪》（**Bones)**真有那么好看吗? 为啥能拍到第**10**季
尤其在第11季开始booth失踪，bones在尸骨间独自一个人拿着骨头，简直泪奔 2.每个人都是独立的个体，都有不一样的性格特征， …

深度学习网络中**backbone**是什么意思**? -** 知乎
1.backbone: 翻译为主干网络的意思，既然说是主干网络，就代表其是网络的一部分，那么是哪部分呢? 翻译的很好，主干部分， …

如何评价育碧的《碧海黑帆 **Skull & Bones**》? **-** 知乎
而最近育碧居然也这么玩儿了！育碧新作《碧海黑帆》（Skull & Bones），就是以《刺客信条：黑旗》的海战部分作为蓝本，开发 …

如何评价骨头社（**BONES**）的动画？ - 知乎
相比较现在的许多大厂，bones的产量是不高的，一般年产3~6部左右，这对于一个老牌动画制作公司而言是可以接受的。可如果你 …

如何评价骨头社（*BONES*）的动画？ - 知乎
BONES是1998年成立的新公司，是家管理型的公司，成名的时候还算是年轻的。制作过的作品不多，但是类型挺丰富的，什么风格 …

Explore the intricate structure of the bones in the wrist and hand. Understand their functions and significance for movement. Learn more in our detailed guide!

Back to Home