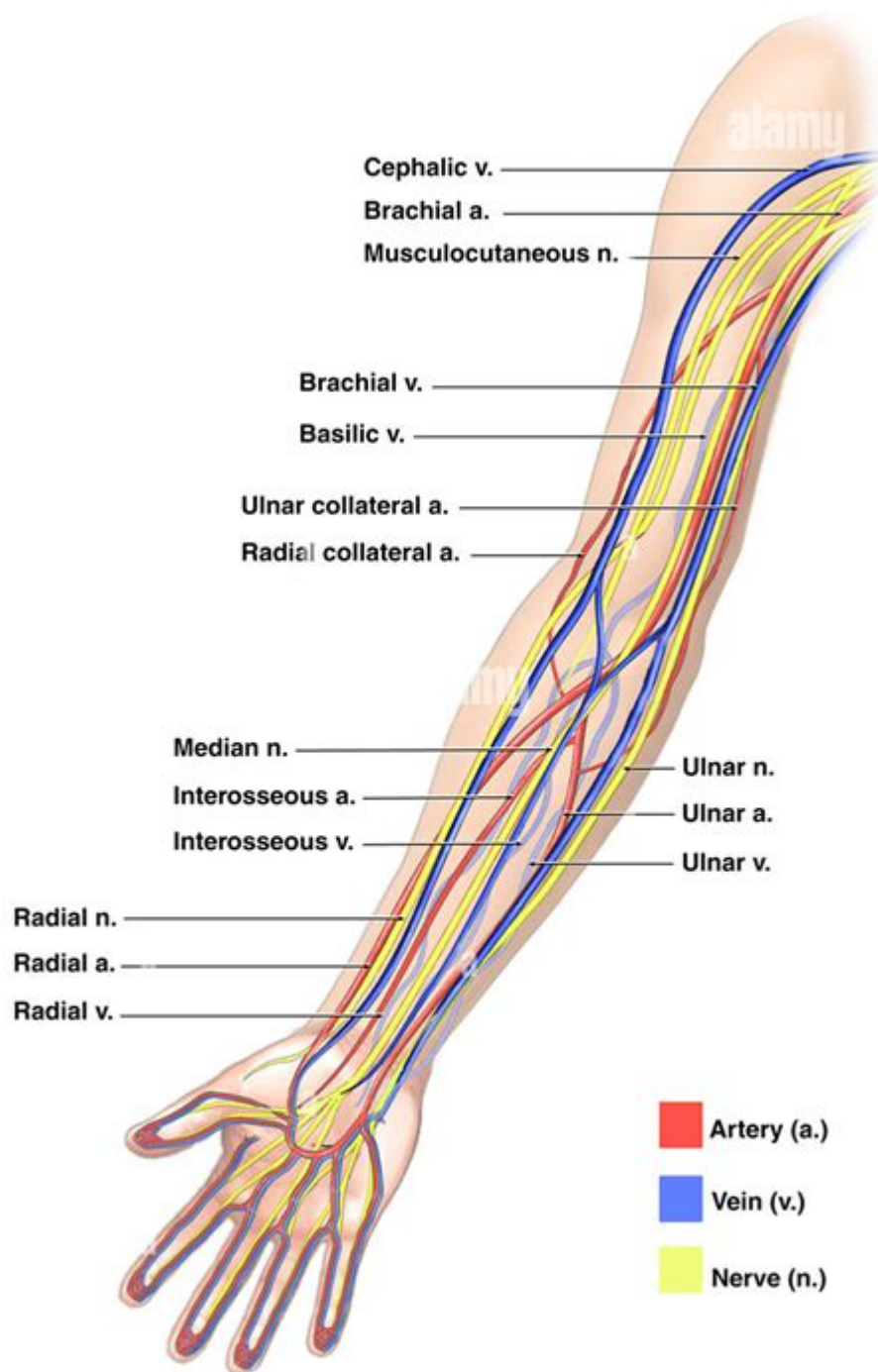


Arm Artery And Vein Anatomy



alamy

Image ID: ADTRP3
www.alamy.com

Arm artery and vein anatomy is a crucial aspect of human physiology, playing a significant role in the circulatory system. The arteries and veins of the arm are responsible for transporting blood to and from the heart, ensuring that oxygen and nutrients reach the tissues while removing carbon dioxide and waste products. Understanding the anatomy of these blood vessels is essential for medical professionals and anyone interested in human biology. This article will provide a detailed overview of the arm's arterial and venous systems, including their structures, functions, and clinical significance.

Overview of the Circulatory System in the Arm

The circulatory system consists of a complex network of arteries, veins, and capillaries that work together to maintain blood flow throughout the body. In the arm, this system is divided into two main components: the arterial system, which carries oxygenated blood from the heart, and the venous system, which returns deoxygenated blood back to the heart.

Arterial Anatomy of the Arm

The arterial supply of the arm begins at the heart and extends to the fingers. The primary arteries involved include:

Brachial Artery

- The brachial artery is the main arterial supply of the arm, branching from the axillary artery as it passes the lower border of the teres major muscle.
- It runs along the medial aspect of the humerus and is typically found in the anterior compartment of the arm.
- The brachial artery bifurcates into the radial and ulnar arteries at the elbow, around the level of the radial head.

Radial Artery

- The radial artery branches off from the brachial artery and travels down the lateral (thumb) side of the forearm.
- It supplies blood to the lateral side of the forearm and the hand.
- The radial artery is often palpated at the wrist for pulse assessment and is commonly used for arterial blood gas sampling.

Ulnar Artery

- The ulnar artery is the second major branch of the brachial artery, running along the medial (pinky) side of the forearm.
- It supplies blood to the medial side of the forearm and contributes to the formation of the superficial and deep palmar arches in the hand.
- The ulnar artery is larger than the radial artery and is also important for pulse detection.

Common Interosseous Artery

- The common interosseous artery branches from the ulnar artery and divides into the anterior and posterior interosseous arteries.
- These arteries supply the deep structures of the forearm, including muscles, bones, and joints.

Palmar Arches

- The superficial palmar arch is primarily formed by the ulnar artery, with contributions from the radial artery.
- The deep palmar arch is primarily formed by the radial artery, with contributions from the ulnar artery.
- These arches give rise to the digital arteries that supply the fingers.

Venous Anatomy of the Arm

The venous system of the arm is responsible for returning deoxygenated blood to the heart. The main veins include:

Superficial Veins

- The cephalic vein runs along the lateral side of the forearm and arm, draining into the axillary vein.
- The basilic vein runs along the medial side and eventually joins the brachial vein to form the axillary vein.
- The median cubital vein is a short vein that connects the cephalic and basilic veins at the elbow, commonly used for venipuncture.

Deep Veins

- The deep veins of the arm are typically paired and accompany the arteries. They include the brachial veins, which run alongside the brachial artery.
- The radial and ulnar veins accompany the radial and ulnar arteries, respectively.
- These deep veins ultimately drain into the axillary vein, which continues as the subclavian vein.

Anatomical Variations

Anatomical variations in the arterial and venous systems of the arm can occur and may influence clinical practice. Some common variations include:

- Duplicated veins: Some individuals may have multiple veins accompanying the arteries.

- Variations in branching patterns: The radial and ulnar arteries may arise from the brachial artery at different levels or have different paths.
- Presence of accessory veins: Additional veins may be present in some individuals.

Understanding these variations is essential for surgical procedures and for diagnosing vascular diseases.

Clinical Significance

The anatomy of the arm arteries and veins is significant in various clinical contexts:

1. Vascular Access

- Understanding the location of major veins, such as the median cubital vein, is crucial for healthcare professionals performing blood draws or IV placements.
- The radial artery is often used for arterial line placements in critical care settings.

2. Peripheral Artery Disease (PAD)

- PAD can affect the blood flow in the arteries of the arm, leading to symptoms such as pain, numbness, and weakness.
- Early recognition of PAD is important for preventing complications such as limb ischemia.

3. Thrombosis and Embolism

- Deep vein thrombosis (DVT) can occur in the arm, particularly in individuals with hypercoagulable states or after prolonged immobilization.
- Understanding the venous anatomy helps in diagnosing and managing such conditions.

4. Surgical Interventions

- Knowledge of the arm's vascular anatomy is critical for surgical interventions, including bypass grafting and tumor resections.
- Surgeons must be aware of the location of arteries and veins to minimize complications and ensure proper healing.

Conclusion

In summary, the arm artery and vein anatomy forms an intricate network of blood vessels that is vital for maintaining blood circulation in the upper extremities. The brachial, radial, and ulnar arteries, along with the cephalic and basilic veins, play essential roles in supplying and draining blood. Variations in anatomy can have significant implications in clinical practice, emphasizing the need for a thorough understanding of this system. Knowledge of the arm's vascular anatomy is invaluable for healthcare providers, particularly in surgical settings, diagnostic assessments, and the management of vascular diseases. Understanding this anatomy not only aids in medical procedures but also enhances the overall understanding of human physiology.

Frequently Asked Questions

What are the main arteries of the arm?

The main arteries of the arm include the subclavian artery, axillary artery, brachial artery, radial artery, and ulnar artery.

What is the function of the brachial artery?

The brachial artery supplies oxygenated blood to the upper arm and branches into the radial and ulnar arteries to supply the forearm and hand.

Where is the cephalic vein located?

The cephalic vein is located on the lateral side of the forearm and arm, running along the outer side of the biceps muscle.

What are the differences between veins and arteries in the arm?

Arteries carry oxygenated blood away from the heart under higher pressure, while veins carry deoxygenated blood back to the heart under lower pressure.

What is the role of the radial artery?

The radial artery supplies blood to the lateral aspect of the forearm and is commonly used for measuring pulse at the wrist.

What is the anatomical significance of the antecubital fossa?

The antecubital fossa is a crucial area where major vessels like the brachial artery and veins are accessible for venipuncture and is a common site for taking blood pressure.

How do the ulnar and radial arteries communicate?

The ulnar and radial arteries communicate through the superficial and deep palmar arches in the hand, allowing for collateral circulation.

What veins are commonly used for intravenous access in the arm?

The median cubital vein, located in the antecubital fossa, is the most commonly used vein for intravenous access due to its size and superficial location.

What is the significance of the brachial plexus in arm anatomy?

The brachial plexus is a network of nerves that innervates the arm, originating from the spinal nerves C5 to T1, and is crucial for motor and sensory functions.

Find other PDF article:

<https://soc.up.edu.ph/39-point/Book?trackid=nUE46-5877&title=math-110-final-exam.pdf>

Arm Artery And Vein Anatomy

ARM -

3. ARM ARM IP ...

windows arm -

ARM Windows, x86 Windows Windows ARM

Intel AMD x86 ARM MIPS -

X86 ARM ARM ' ' ...

ARM "O1 Arm IP ...

3 arm arm arm CSS IP license arm

X Elite X Plus ARM Windows PC

Aug 13, 2024 · ARM ARM X Elite Windows On ARM ...

2025 / ...

Feb 13, 2025 · ...

arm64aarch64 -

Apple 64 ARM 2013 iPhone 5S A7 Xcode iOS target armv6 armv7 armv7s armv8 arm64

M4M4 ProM4 Max

Nov 4, 2024 · M4ARM3nm 245iPad Pro Mac M3

ARM64WINDOWS

Windows on ARM Windows Windows on ARM UEFI L420UEFI Windows

NX9031 -

“”2023NIO day“”

ARM -

3.ARM ARMIP

windowsarm -

ARMWindows,x86Windows Windows ARM

IntelAMD x86ARMMIPS -

X86 ARM ARM‘’

ARM“O1 Arm IP

3armarm armCSSIP licensearm

X EliteX PlusARM Windows PC

Aug 13, 2024 · ARM ARMX Elite Windows On ARM

2025/

Feb 13, 2025 ·

arm64aarch64 -

Apple 64 ARM 2013 iPhone 5S A7 Xcode iOS target armv6 armv7 armv7s armv8 arm64

M4M4 ProM4 Max

Nov 4, 2024 · M4ARM3nm 245iPad Pro Mac M3

ARM64WINDOWS

Windows on ARM Windows Windows on ARM UEFI L420UEFI Windows

XXXXXXXXXXXX NX9031 -
XXXXXXXXXXXX“”XXXXXXXXXXXX2023XXXXXXXXXXXXNIO dayXXXXXXXXXXXX“” ...

Explore the intricate arm artery and vein anatomy with our detailed guide. Understand their functions and relationships. Learn more about your body's design!

[Back to Home](#)