Anatomy Of Foot Ankle

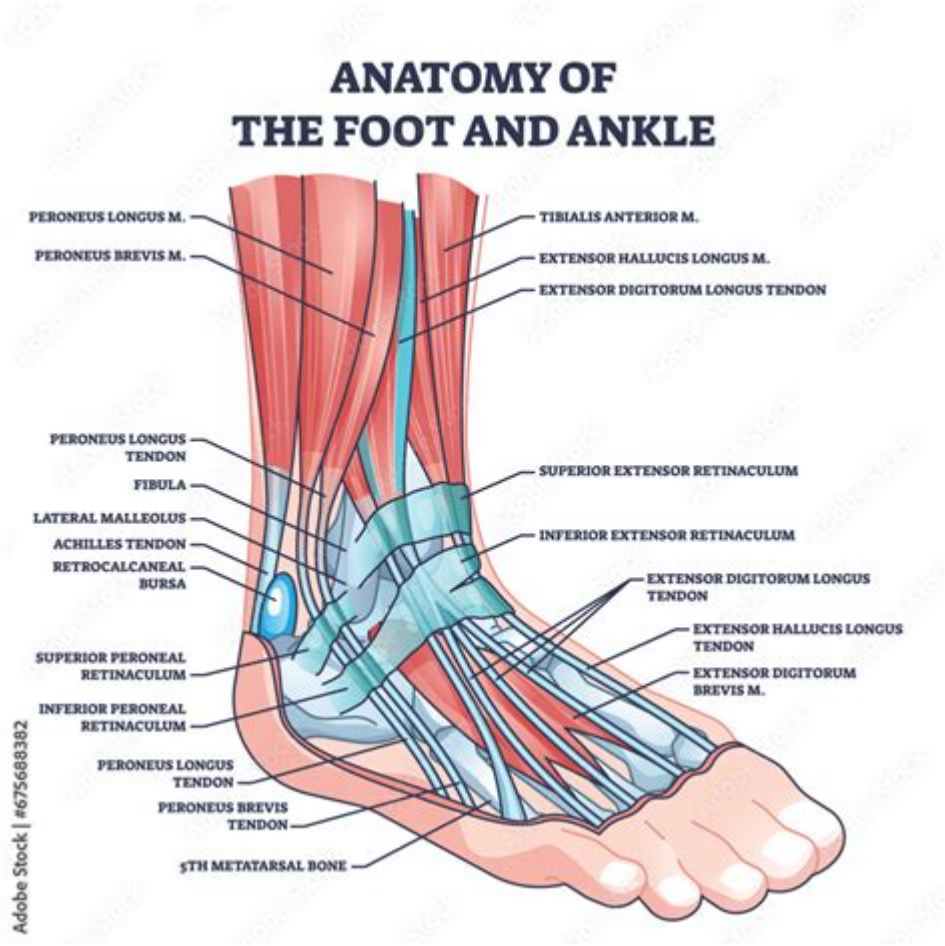

Anatomy of Foot Ankle is a complex and intricate system that plays a crucial role in human mobility and functionality. The foot and ankle are composed of numerous bones, joints, muscles, tendons, and ligaments, working together to provide support, balance, and movement. The anatomy of the foot and ankle is essential for understanding how we walk, run, and engage in various physical activities. This article will delve into the structural components of the foot and ankle, their functions, and common injuries associated with them.

Overview of the Foot and Ankle Structure

The foot and ankle consist of several key structures that enable their function:

1. Bones: The foot has 26 bones, while the ankle comprises 3 primary bones.
2. Joints: Several joints facilitate movement and flexibility.
3. Muscles and Tendons: These structures enable movement, support, and stabilization.
4. Ligaments: Ligaments connect bones to other bones, providing stability.

Bones of the Foot and Ankle

The human foot is divided into three main sections: the forefoot, midfoot, and hindfoot.

1. Forefoot

The forefoot is composed of:

- Phalanges: The 14 bones that make up the toes (2 in the big toe, 3 in each of the other toes).
- Metatarsals: The 5 long bones in the midsection of the foot that connect to the toes.

2. Midfoot

The midfoot consists of 5 tarsal bones:

- Navicular: Located on the medial side of the foot, this bone connects the talus to the cuneiform bones.
- Cuneiform Bones: Three bones (medial, intermediate, and lateral) that support the arch of the foot.
- Cuboid: A cube-shaped bone that connects the foot's lateral side to the ankle.

3. Hindfoot

The hindfoot includes:

- Talus: The ankle bone that connects the leg to the foot.
- Calcaneus: The heel bone, which is the largest bone in the foot.

The ankle joint is formed by the articulation between the tibia, fibula, and talus.

Joints of the Foot and Ankle

Several joints are integral to the movement and stability of the foot and ankle:

1. Ankle Joint (Talocrural Joint)

The primary joint of the ankle, it allows for dorsiflexion and plantarflexion, enabling the foot to move up and down. It is formed by:

- Tibia: The larger of the two bones in the lower leg.
- Fibula: The smaller bone that runs parallel to the tibia.

- Talus: The bone that sits on top of the heel bone (calcaneus).

2. Subtalar Joint

Located beneath the talus, this joint allows for inversion and eversion of the foot, which is essential for adapting to uneven surfaces.

3. Midtarsal Joint

This joint consists of two articulations between the talus and navicular, and the calcaneus and cuboid, contributing to the foot's flexibility.

Muscles and Tendons of the Foot and Ankle

Muscles and tendons play a vital role in foot and ankle movement. They can be categorized into two main groups: extrinsic and intrinsic muscles.

1. Extrinsic Muscles

These muscles originate in the lower leg and affect foot movement through their tendons:

- Anterior Compartment:
- Tibialis Anterior: Dorsiflexes and inverts the foot.
- Extensor Hallucis Longus: Extends the big toe and aids in dorsiflexion.
- Extensor Digitorum Longus: Extends the toes and assists in dorsiflexion.

- Lateral Compartment:
- Fibularis Longus: Evert and plantarflex the foot.
- Fibularis Brevis: Evert the foot and assist in plantarflexion.

- Posterior Compartment:
- Gastrocnemius: Powerful plantarflexor of the foot.
- Soleus: Works with the gastrocnemius to aid in plantarflexion.
- Tibialis Posterior: Inverts and plantarflexes the foot.

2. Intrinsic Muscles

These muscles are located within the foot itself and contribute to its stability and dexterity:

- Flexor Hallucis Brevis: Flexes the big toe.
- Adductor Hallucis: Adducts the big toe.

- Lumbricals: Flex the metatarsophalangeal joints while extending the interphalangeal joints.
- Interossei Muscles: Aid in toe abduction and adduction.

Ligaments of the Foot and Ankle

Ligaments are vital for maintaining stability in the foot and ankle. The major ligaments include:

1. Lateral Ligaments

These ligaments provide support on the outer side of the ankle:

- Anterior Talofibular Ligament (ATFL): Prevents anterior displacement of the talus.
- Calcaneofibular Ligament (CFL): Stabilizes the subtalar joint.
- Posterior Talofibular Ligament: Provides support for the ankle joint.

2. Medial Ligaments (Deltoid Ligament)

The deltoid ligament provides stability on the inner side of the ankle:

- Composed of several smaller ligaments, it helps prevent excessive eversion.

3. Plantar Ligaments

These ligaments support the arch of the foot:

- Plantar Fascia: A thick band of tissue that supports the arch and absorbs shock.

Common Injuries of the Foot and Ankle

Understanding the anatomy of the foot and ankle also involves acknowledging potential injuries that can occur due to trauma, overuse, or structural abnormalities.

1. Ankle Sprains

Ankle sprains occur when the ligaments are stretched or torn. They are classified as:

- Grade I: Mild stretching of ligaments.
- Grade II: Partial tearing of ligaments.
- Grade III: Complete tearing of ligaments.

2. Fractures

Foot and ankle fractures can occur due to trauma or stress:

- Ankle Fractures: Often involve the fibula and/or tibia.
- Metatarsal Fractures: Commonly known as "march fractures," often due to overuse.

3. Tendon Injuries

Tendons can become inflamed or torn due to repetitive use:

- Achilles Tendinitis: Inflammation of the Achilles tendon.
- Plantar Fasciitis: Inflammation of the plantar fascia, causing heel pain.

Conclusion

The anatomy of the foot and ankle is a remarkable system that allows for a wide range of movements and functions essential to daily life. Understanding the bones, joints, muscles, tendons, and ligaments involved provides insight into how we maintain balance, support our body weight, and execute various activities. Awareness of common injuries can also aid in prevention and treatment, ensuring optimal foot and ankle health. By maintaining strength, flexibility, and proper mechanics, individuals can enhance their mobility and reduce the risk of injuries in this vital area of the body.

Frequently Asked Questions

What are the main bones that make up the foot and ankle?

The main bones of the foot and ankle include the tibia, fibula, talus, calcaneus, navicular, cuboid, and the three cuneiform bones, along with the five metatarsals and 14 phalanges.

What is the role of the Achilles tendon in foot anatomy?

The Achilles tendon connects the calf muscles to the heel bone (calcaneus) and is crucial for walking, running, and jumping, allowing for the extension of the foot at the ankle.

How many arches are present in the human foot, and what are their functions?

There are three main arches in the human foot: the medial longitudinal arch, the lateral longitudinal arch, and the transverse arch. They help distribute weight, absorb shock, and provide balance.

What ligaments are important for ankle stability?

Key ligaments that provide ankle stability include the anterior talofibular ligament, calcaneofibular ligament, and posterior talofibular ligament, along with the deltoid ligament on the medial side.

What is the significance of the subtalar joint in foot movement?

The subtalar joint, located between the talus and calcaneus, allows for inversion and eversion of the foot, playing a vital role in adapting to uneven surfaces and maintaining balance.

What are common injuries associated with the foot and ankle?

Common injuries include ankle sprains, fractures, plantar fasciitis, Achilles tendonitis, and stress fractures, often resulting from overuse or trauma.

What is plantar fasciitis, and how does it affect foot anatomy?

Plantar fasciitis is an inflammation of the plantar fascia, a thick band of tissue that runs across the bottom of the foot, resulting in heel pain and stiffness, particularly in the morning.

How does the structure of the foot contribute to its function?

The foot's structure, including its bones, joints, ligaments, and muscles, allows for a complex range of movements, providing stability, mobility, and shock absorption during various activities.

What muscles are involved in foot and ankle movement?

Key muscles include the tibialis anterior, gastrocnemius, soleus, peroneus longus, and flexor and extensor muscles of the toes, which facilitate flexion, extension, inversion, and eversion.

Anatomy Of Foot Ankle

人体解剖*1.68*版本自用 - 吾爱破解 - *52pojie.cn*
Apr 24, 2022 · 好多兄弟萌私信我要，今天打包了一下整合了四件套，分享给大家。没想到医学的兄弟萌这么多。直接上链接链接: **https://pan ...**

2020人体解剖学图谱**app - 吾爱破解 - 52pojie.cn**
Mar 24, 2020 · 名称: **2020**人体解剖学图谱**app**破解版版本号: **v2020.0.73** 安卓内购版大小: **802M**系统: **4.X**及以上语言: 中文 **[hr]**简介: **2020**人体解剖学图谱已付费完整版是专为解剖 **...**

医学 美术等人体有关的学生的福利 **human anatomy atlas**免费 - 吾 **...**
Apr 14, 2020 · 打开微软商店，搜索 **human anatomy atlas** 可以看到前面三个当中有两个是免费的，另外还有一个在打折。

求人体解剖学图谱 - 吾爱破解 - *52pojie.cn*
Jun 2, 2021 · 【资源求助】求人体解剖学图谱【复制链接】求人体解剖学图谱

人体解剖图谱（***body Human Anatomy Atlas***）安装 - 百度经验
Nov 10, 2018 · visible body Human Anatomy Atlas，**3D**人体解剖学图谱

是美国波士顿的一家公司开发的人体构造解剖学图谱，通过这款**app**你可以详细了解人体的骨骼、内脏、血管等结构的详细构造，不管是不是从事医疗行业，大家都可以通过这款软件科普一下人体结构知识，如果对这 **...**

医学行业软件**Organon Anatomy**（我是搬运工） **-** 吾爱破解
Jul 25, 2019 · 我最近骨折 在医院里听病友说了一个软件可以模拟人类的骨骼进行活动，是**3D**效果。我向病友打听了这个软件。我在论坛里找到了相关的帖子，可是链接失效了。**https://www.52 ...**

求**Complete Anatomy windows**版，谢谢 **-** 吾爱破解 **- 52pojie.cn**
Apr 2, 2021 · 求**Complete Anatomy windows**版，谢谢 **[**复制链接**] ...** 下一页 **»**
1 2 / 2 页 下一页

Android - 『精品软件区』 **-** 吾爱破解 **- 52pojie.cn**
Mar 21, 2016 · 精品软件推荐，软件交流天地，汇集众多精彩评论，热心会员每日更新。找你所需要的，给你我分享的！这里不但有**PC**软件，安卓、**iPhone**等手机软件也统统包含。

人体解剖***1.68***版本自用 **-** 吾爱破解 ***- 52pojie.cn***
Apr 24, 2022 · 好多兄弟萌私信我要，今天打包了一下整合了四件套，分享给大家。没想到医学的兄弟萌这么多。直接上链接链接: **https://pan ...**

2020人体解剖学图谱**app -** 吾爱破解 **- 52pojie.cn**
Mar 24, 2020 · 名称: **2020**人体解剖学图谱**app**破解版版本号: **v2020.0.73** 安卓内购版大小: **802M**系统: **4.X**及以上语言: 中文 **[hr]**简介: **2020**人体解剖学图谱已付费完整版是专为解剖 **...**

医学美术等人体有关的学生的福利 **human anatomy atlas**免费 **-** 吾 **...**
Apr 14, 2020 · 打开微软商店，搜索 **human anatomy atlas** 可以看到前面三个当中有两个是免费的，另外还有一个在打折。

求人体解剖学图谱 **-** 吾爱破解 **- 52pojie.cn**
Jun 2, 2021 · [资源求助**]** 求人体解剖学图谱 **[**复制链接**]** 求人体解剖学图谱

人体解剖图谱（***body Human Anatomy Atlas***）安装 **-** 百度经验
Nov 10, 2018 · visible body Human Anatomy Atlas ，**3D**人体解剖学图谱是美国波士顿的一家公司开发的人体构造解剖学图谱，通过这款**app**你可以详细了解人体的骨骼、内脏、血管等结构的 **...**

医学行业软件**Organon Anatomy**（我是搬运工） - 吾爱破解

Jul 25, 2019 · 我最近骨折 在医院里听病友说了一个软件可以模拟人类的骨骼进行活动，是**3D**效果。我向病友打听了这个软件。我在论坛里找到了相关的帖子，可是链接失效了 **...**

求**Complete Anatomy windows**版，谢谢 - 吾爱破解 **- 52pojie.cn**

Apr 2, 2021 · 求**Complete Anatomy windows**版，谢谢 **[**复制链接**] ...** 下一页 **»**

1 2 / 2 页 下一页

Android - 『精品软件区』 - 吾爱破解 **- 52pojie.cn**

Mar 21, 2016 · 精品软件推荐，软件交流天地，汇集众多精彩评论，热心会员每日更新。找你所需要的，给你我分享的！这里不但有**PC**软件，安卓、**iPhone**等手机软件也统统包含。

Explore the intricate anatomy of the foot and ankle

Back to Home