Anatomy Of The Mediastinum

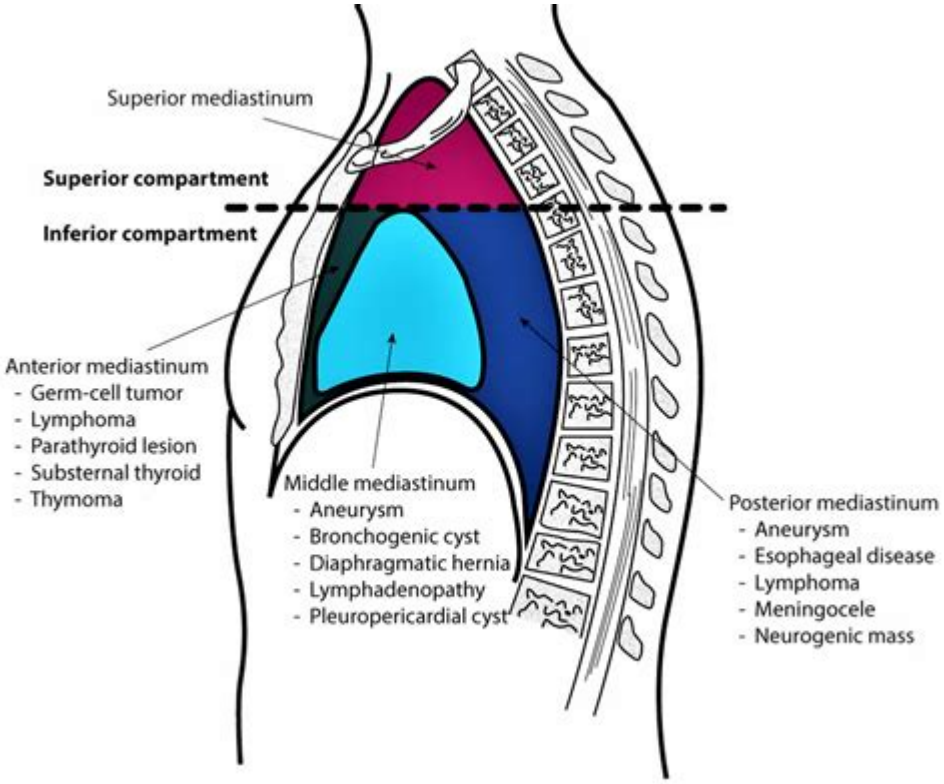

Introduction to the Mediastinum

The **mediastinum** is a critical anatomical region located in the thoracic cavity, serving as a central compartment that houses various vital structures. It is bordered by the lungs laterally, the sternum anteriorly, and the vertebral column posteriorly. The mediastinum plays a significant role in respiratory and cardiovascular systems, acting as a passageway for nerves, blood vessels, and lymphatics. Understanding its anatomy is essential for diagnosing and managing conditions affecting this area.

Divisions of the Mediastinum

The mediastinum is traditionally divided into four main compartments, each with distinct anatomical features and clinical significance:

1. Superior Mediastinum

The superior mediastinum is located above a horizontal line drawn from the sternal angle to the intervertebral disc between T4 and T5. It contains

several critical structures:

- Thymus Gland: This gland is responsible for T-cell maturation and is more prominent in children.
- Great Vessels: The aorta (ascending, arch, and descending), pulmonary arteries, and veins pass through this area.
- Trachea: The trachea descends into the thorax from the neck.
- Esophagus: This muscular tube connects the throat with the stomach.
- Nerves: Key nerves such as the vagus nerve, phrenic nerve, and sympathetic trunks traverse the superior mediastinum.

2. Anterior Mediastinum

The anterior mediastinum is situated between the sternum and the pericardium. Its contents include:

- Thymus: In adults, it is usually small and replaced by fatty tissue.
- Lymph Nodes: These are involved in immune responses.
- Connective Tissue: Contains loose areolar tissue.

Common pathologies in this region include thymomas and lymphomas.

3. Middle Mediastinum

The middle mediastinum is primarily occupied by the heart and pericardium. Key components include:

- Heart: The muscular organ responsible for pumping blood throughout the body.
- Pericardium: A double-walled sac surrounding the heart.
- Great Vessels: The ascending aorta, pulmonary arteries, and veins.
- Bronchi: The main bronchi branch off from the trachea.
- Nerves: The cardiac plexus, which regulates heart function.

Conditions such as pericarditis and cardiac tumors often originate from this area.

4. Posterior Mediastinum

The posterior mediastinum lies behind the pericardium and contains:

- Esophagus: Transmits food and liquids from the throat to the stomach.
- Thoracic Aorta: The descending part of the aorta that supplies blood to the lower body.
- Azygos and Hemiazygos Veins: These veins drain blood from the thoracic wall

and empty into the superior vena cava.
- Nerves: The thoracic sympathetic trunks and splanchnic nerves.

This compartment is often involved in conditions such as esophageal cancer and aortic aneurysms.

Anatomical Relationships

Understanding the relationships between the structures in the mediastinum is crucial for clinicians and surgeons. Here are a few key anatomical relationships:

- Vascular Structures: The great vessels are closely associated with the heart, with the aorta arching over the left main bronchus.
- Nerve Pathways: The vagus nerve runs along the carotid sheath and gives off branches to the heart and lungs.
- Esophageal Location: The esophagus runs posterior to the trachea and anterior to the aorta, making it susceptible to compression by adjacent structures.

Clinical Significance

The mediastinum is a site of various pathological conditions, and its anatomy is essential in the clinical setting. Some common clinical considerations include:

1. Mediastinal Masses

Mediastinal masses can arise from various tissues, leading to a range of symptoms. Common types of mediastinal masses include:

- Thymoma: A tumor of the thymus gland, often associated with myasthenia gravis.
- Lymphoma: Malignancies of the lymphatic system that can affect lymph nodes in the mediastinum.
- Teratoma: A germ cell tumor that may contain various types of tissues.

2. Mediastinitis

Mediastinitis is an inflammation of the mediastinal tissues, often resulting from infections, trauma, or post-surgical complications. Symptoms may include:

- Chest pain
- Fever
- Tachycardia
- Shortness of breath

Early diagnosis and treatment are vital to prevent severe complications.

3. Esophageal Disorders

Conditions affecting the esophagus, such as reflux disease or esophageal cancer, can present with symptoms that may be initially attributed to heart problems. Thus, a thorough understanding of the mediastinum aids in accurate diagnosis.

4. Vascular Pathologies

The thoracic aorta can develop aneurysms or dissections, often presenting with severe chest pain. Understanding the anatomy of the mediastinum is critical for timely interventions in these life-threatening conditions.

Imaging Techniques

To visualize the mediastinum and its structures, various imaging modalities are utilized:

- Chest X-ray: Provides a preliminary overview of the mediastinal contours and any obvious masses.
- Computed Tomography (CT) Scan: Offers detailed cross-sectional images and is particularly useful in evaluating mediastinal masses and vascular abnormalities.
- Magnetic Resonance Imaging (MRI): Useful for soft tissue characterization and assessing the pericardium and surrounding structures.
- Ultrasound: Occasionally used, especially for assessing fluid collections or masses adjacent to the heart.

Conclusion

The mediastinum is an intricate and vital area of human anatomy, encompassing various structures that play essential roles in respiratory and cardiovascular health. A comprehensive understanding of its anatomy, divisions, and clinical significance is crucial for healthcare professionals in diagnosing and managing conditions affecting this region. As medical imaging techniques continue to advance, a clearer picture of the mediastinum

will emerge, further enhancing our understanding and treatment of related pathologies.

Frequently Asked Questions

What are the main divisions of the mediastinum?

The mediastinum is divided into the superior mediastinum and the inferior mediastinum, which is further subdivided into anterior, middle, and posterior mediastinum.

What structures are found in the superior mediastinum?

The superior mediastinum contains the thymus gland, great vessels (such as the aortic arch and its branches), trachea, esophagus, thoracic duct, and various nerves including the vagus and phrenic nerves.

What is the clinical significance of the mediastinum?

The mediastinum is clinically significant because it houses critical structures such as the heart, major blood vessels, and airways. Pathologies like mediastinal tumors, lymphadenopathy, and infections can significantly affect respiratory and cardiovascular function.

How does the anatomy of the mediastinum vary in children compared to adults?

In children, the thymus gland is larger and occupies more space in the mediastinum, gradually decreasing in size as they grow. This can influence the presentation of mediastinal masses and respiratory issues in pediatric patients.

What imaging techniques are commonly used to evaluate the mediastinum?

Common imaging techniques for evaluating the mediastinum include chest X-rays, computed tomography (CT) scans, and magnetic resonance imaging (MRI), which help in identifying abnormalities such as masses, lymphadenopathy, or fluid collections.

What is the role of the mediastinum in the immune system?

The mediastinum plays a role in the immune system primarily through the thymus gland, where T-lymphocytes mature. It also contains lymph nodes that

help filter lymphatic fluid and respond to infections.

Anatomy Of The Mediastinum

人体解剖**1.68**版本自用 **- 吾爱破解 - 52pojie.cn**
Apr 24, 2022 · 好多兄弟萌私信我要，今天打包了一下整合了四件套，分享给大家。没想到医学的兄弟萌这么多。直接上链接链接: https://pan ...

2020人体解剖学图谱**app - 吾爱破解 - 52pojie.cn**
Mar 24, 2020 · 名称: 2020人体解剖学图谱app破解版版本号: v2020.0.73 安卓内购版大小: 802M系统: 4.X及以上语言: 中文 [hr]简介: 2020人体解剖学图谱已付费完整版是专为解剖 ...

医学 美术等人体有关的学生的福利 **human anatomy atlas**免费 **- 吾 ...**
Apr 14, 2020 · 打开微软商店，搜索 human anatomy atlas 可以看到前面三个当中有两个是免费的，另外还有一个在打折。

求人体解剖学图谱 **- 吾爱破解 - 52pojie.cn**
Jun 2, 2021 · [资源求助] 求人体解剖学图谱 [复制链接] 求人体解剖学图谱

人体解剖图谱（*body Human Anatomy Atlas*）安装 - 百度经验
Nov 10, 2018 · visible body Human Anatomy Atlas，3D人体解剖学图谱是美国波士顿的一家公司开发的人体构造解剖学图谱，通过这款app你可以详细了解人体的骨骼、内脏、血管等结构的 ...

医学行业软件Organon Anatomy（我是搬运工）- 吾爱破解
Jul 25, 2019 · 我最近骨折 在医院里听病友说了一个软件可以模拟人类的骨骼进行活动，是3D效果。我向病友打听了这个软件。我在论坛里找到了相关的帖子，可是链接失效了 ...

求**Complete Anatomy windows**版，谢谢 **- 吾爱破解 - 52pojie.cn**
Apr 2, 2021 · 求Complete Anatomy windows版，谢谢 [复制链接] ... 下一页 » 1 2 / 2 页 下一页

Android - 『精品软件区』 - 吾爱破解 - 52pojie.cn
Mar 21, 2016 · 精品软件推荐，软件交流天地，汇集众多精彩评论，热心会员每日更新。找你所需要的，给你我分享的！这里不但有PC软件，安卓、iPhone等手机软件也统统包含。

คู่มือปฏิบัติงาน
หัวใจเป็นอวัยวะกล้ามเนื้ อตั งอยูภายในกึ่งกลางทรวงอก (mediastinum) หลังต่อกระดูกสันอก (Sternum) และอยู่หน้ากระดูกสันหลัง (vertebral column) ถูก ...

CHEST WALL ANATOMY & MEDIASTINUM
MEDIASTINUM The thoracic mediastinum is the compartment that runs the length of the thoracic cavity between the pleural sacs of the lungs. This compartment extends longitudinally from the ...

Radiographic Features of Mediastinal Anatomy - CHEST
RADIOGRAPHIC FEATURES OF MEDIAmNAl ANATOMY 609 FIGURE 2. Computed tomographic

scan of the chest indicating the normal cross-sectional anatomy of the …

THORAX THORAX OVERVIEW (FROM SNELL'S ANATOM
THORAX OVERVIEW (FROM SNELL'S ANATOMY) The adult sternum consist of three parts: Manubrium, body and xiphoid process

The clinical anatomy of the Thorax - USMF
The Superior Mediastinum lies between the manubrium sterni in front, and the upper thoracic vertebra behind. It contains: the origins of the Sternohyoidei and Sternothyreoidei and the …

Anatomy and Physiology of the Thoracic Lymphatic System
Thoracic lymphatics play a significant role in the immune system of intrathoracic organs such as the lungs, pleura, esophagus, and mediastinum. Its network of lymphatic vessels carries …

Body Anatomy
Title: Mediastinum Description: Cross-sectional anatomy of the mediastinum Author(s): E Del Vescovo, S McLenachan

Ryan Ch04.qxd - Elsevier
The middle mediastinum is occupied by the heart and its vessels. The anterior mediastinum is between the anterior part of the heart and the sternum. The posterior mediastinum is between …

Anatomy of Oesophagus
Anatomy of Oesophagus The oesophagus is a fibromuscular tube approximately 25 cm long in adults, extending from the lower end of the pharynx (C6) to the stomach's cardiac end (T11). It …

Chapter 4 Mediastinum - Springer
Anatomical Compartments The mediastinum is the anatomical space in the midline of the thorax, lying between the two lungs and their visceral pleura. It extends from the thoracic inlet …

Body Anatomy - University of Edinburgh
Title: Mediastinum Description: Cross-sectional anatomy of the mediastinum Author(s): E Del Vescovo, S McLenachan

Anatomy of the mediastinum during life - Taylor & Francis Online
Anatomy of the mediastinurn during life An exact and detailed conception of the anatomy of the mediastinum in living man can be obtained by comparing anatomic specimens with …

Index [onlinelibrary.wiley.com]
81 227, 228 middle mediastinum middle nasal meatus 74 13, 14 middle (P2) phalanges 180, 224 milk teeth milk vein milk well 16 78, 168 78, 168 minor duodenal papilla 130 mitral valve 76, 88 …

Lymphatics of the Mediastinum, Esophagus and Lungs: Thoracic …
The posterior parietal chain ascends in the posterior mediastinum along the vertebral column and it gathers intercostal lymphatics which drain the chest wall, the posterior pleura and the …

Nuclear Cardiology, Part 1: Anatomy and Function of the Normal …
This is the first article of a four-part series on nuclear cardi ology. This article introduces and reviews the anatomy and function of the normal heart. Future articles will develop the …

CT Imaging of the Mediastinum - Springer

Anatomy and Compartments of the Mediastinum This chapter follows Fraser’s mediastinal classifi - cation of anterior, middle, and posterior mediasti-num based on lateral chest X-ray images …

Microsoft Word - 1 ABS Thorax.doc - Partners HealthCare
Explain three functions of the cardiac skeleton. Explain the boundaries and basic organization of the mediastinum. Describe the structures located in the anterior mediastinum, middle …

superior Mediastinum - GMCH
Superior mediastinum • Posterior to the sternum & anterior to the bodies of first four thoracic vertebra

Ultrasound anatomy of the neck: The infrahyoid region
Its name reflects the fact that it provides a route for the diffusion of inflammatory or neoplastic lesions from the retropharyngeal space to the posterior mediastinum [1].

Anatomy of the Thoracic Wall, Pulmonary Cavities, and Mediastinum
Abstract This chapter will review the anatomy of the mediastinum and pulmonary cavities within the thorax and their contents. The wall of the thorax and its asso-ciated muscles, nerves, and …

Body Anatomy
Title: Mediastinum Description: Cross-sectional anatomy of the mediastinum Author(s): E Del Vescovo, S McLenachan

Anatomy of the Thymus Gland - theclinics.com
GROSS ANATOMY Anatomically, the earliest preserved drawings of the gland were the line drawings of Vesalius. Ber-tolini in 1684 gave a very lucid description of the gland with …

Mediasten Anatomisi EŞH EBUS KURSU 5 HAZİRAN 2023.pptx
Mediastinum Transvers çizginin altında diyafragmaya kadar uzanan kısım mediastinum inferior.

Preface - theclinics.com
This issue of Thoracic Surgery Clinics is the second of two parts devoted to the study of thoracic anatomy. It is written by surgeons who possess detailed knowledge of a particular segment of …

Clinical Anatomy of the Pleural Cavity & Mediastinum
Mediastinal Masses Fro From Netter etter 1988 1988 Anterior mediastinum: “four Ts”— Thymoma, Thyroid tumor, Terrible lymphoma, Teratoma

Unit 26: Thorax - MEFST
Superior Mediastinum Thymus Arteries Arch of Aorta Ligamentum Arteriosum Branches of Arch: Brachiocephalic Trunk Left Common Carotid Artery Left Subclavian Artery Veins …

Body Anatomy - University of Edinburgh
Title: Mediastinum Description: Cross-sectional anatomy of the mediastinum Author(s): E Del Vescovo, S McLenachan

Chest Radiology for Dummies: - Deranged Physiology
The ANATOMY: Thorax The ANATOMY: Mediastinum The Steps to Take: 1st thing: QUALITY! Is this film worth looking at? Look at both films simultaneously + COMPARE WITH PREVIOUS

Role of EUS for the evaluation of mediastinal adenopathy

In the anterior mediastinum, endobronchial US (EBUS) visualizes and directs transbronchial FNA of mediastinal adenopathy. This guideline is an update of a previous ASGE document2 and …

ANATOMY OF CARDIOVASCULAR SYSTEM - philadelphia.edu.jo
The heart lies in the mediastinum (me»-de»-as-TI»-num), an anatomical region that extends from the sternum to the vertebral column, from the first rib to the diaphragm, and between the lungs …

FUNCTIONAL ANATOMY AND PHYSIOLOGY OF MALE …
Beneath this structure is a dense, thick connective capsule – tunica albuginea, from which septa radiate to the mediastinum testes except in stallion to form the lobules of the testis.

Body Anatomy
Title: Mediastinum Description: Cross-sectional anatomy of the mediastinum Author(s): E Del Vescovo, S McLenachan

Anatomy of the superior mediastinum - anaesthesiajournal.co.uk
The mediastinum is defined as the region sandwiched between the pleural cavity on either side. It is divided by an imaginary line that passes from the manubriosternal junction (the angle of …

Mediastinal and Hilar Lymphadenopathy: Cross-Referenced Anatomy …
The accurate evaluation of mediastinal and pulmonary hilar lymphadenopathy, es-pecially in patients with lung cancer, is important for determining treatment options and evaluating the …

GROSS ANATOMY of THE OESOPHAGUS - KorAcademy
THORACIC PART In the thorax, it passes downward and to the left through superior then to posterior mediastinum At the level of the sternal angle, the aortic arch pushes the esophagus …

Mediastinum - medclubhu.weebly.com
superior mediastinum. inferior mediastinum ,which is further partitioned into the anterior(2), middle (3) ,and posterior mediastinum (4)by the heart and pericardium.

Human Anatomy, First Edition McKinley&O'Loughlin
A bilobed structure located within the mediastinum superior to the heart and immediately posterior to the sternum. Size of the thymus varies between individuals.

Imaging of the Middle and Visceral Mediastinum
NORMAL ANATOMY AND IMAGING TECHNIQUE The mediastinum contains several vascular and nonvascular structures and its division into different compartments is crucial for …

Mediastinum - medclubhu.weebly.com
superior mediastinum. inferior mediastinum ,which is further partitioned into the anterior(2), middle (3) ,and posterior mediastinum (4)by the heart and pericardium.

Understanding Lymphatic Anatomy and Abnormalities at Imaging
(A) The thoracic duct anatomy is highly variable, with the most commonly described varia-tion including a single duct ascending on the right, crossing midline between T5 and T7, and then …

Anatomy of the Thoracic Duct
The origin of the thoracic duct starts at the supe-rior pole of the cisterna chyli, traverses the aortic hiatus of the diaphragm (see Fig. 2), and then ascends the posterior mediastinum, to the right …

Neuroradiology Primer: Basic Anatomy and Study Interpretation
Neuroradiology Primer: Basic Anatomy and Study Interpretation Benjamin Y. Huang, MD, MPH Department of Radiology University of North Carolina School of Medicine

c01.indd - antoniogoliveira.com
Although there are many good anatomy and physiol-ogy texts that focus on humans, there is a paucity of such options for animals. Since animals have distinct physiological and anatomical …

Anatomi dan Fisiologi Pleura - ResearchGate
Pleura merupakan membran serosa yang melingkupi parenkim paru, mediastinum, diafragma serta tulang iga; terdiri dari pleura viseral dan pleura parietal.1,2 Rongga pleura terisi sejumlah …

Clinical Anatomy of the Pleural Cavity & Mediastinum
Mediastinal Masses Fro From Netter etter 1988 1988 Anterior mediastinum: “four Ts”— Thymoma, Thyroid tumor, Terrible lymphoma, Teratoma

The anterior mediastinum: anatomy and imaging procedures
Finally, the anterior mediastinum communi-cates widely with the neck, middle mediastinum and, through the sternal fasciae of the diaphragm, with the preperitoneal lax connective tissue of …

Anatomy of the Heart - Springer
Introduction The exact anatomy of the heart is best determined intraoperatively via a midline sternotomy that shows the surgical anatomy that the surgeon is concerned about while doing …

Explore the anatomy of the mediastinum

Back to Home