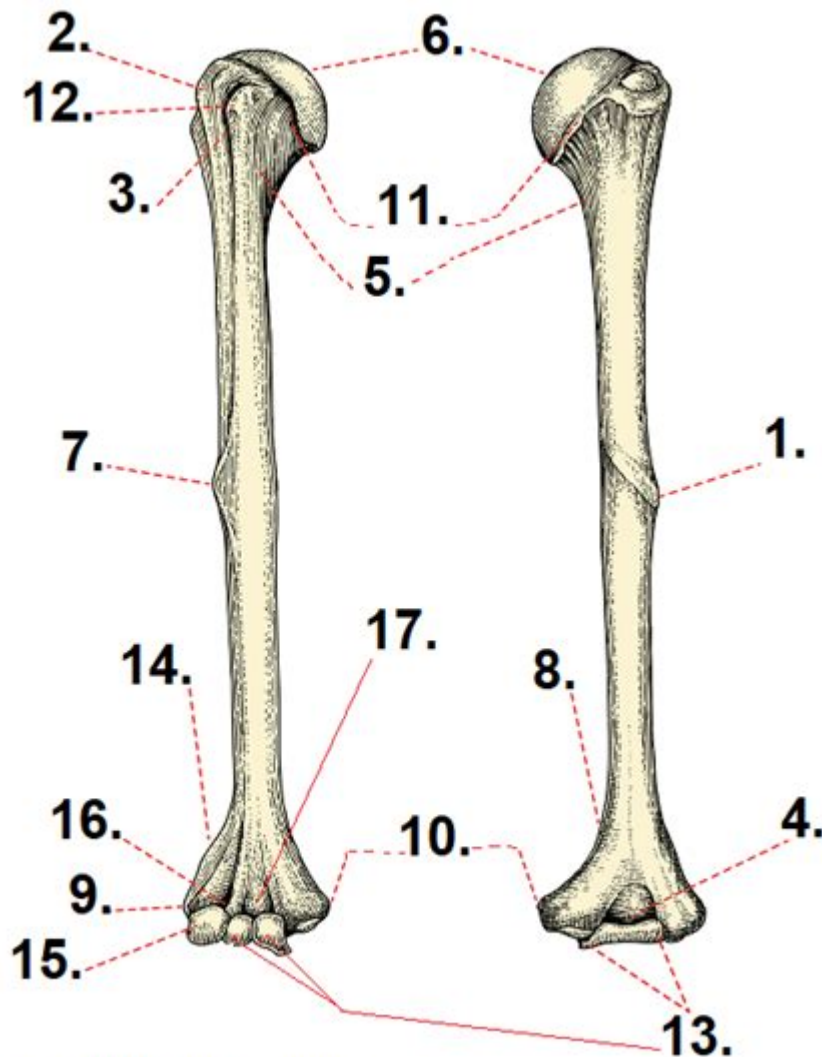


Anatomy Of The Humerus Quiz



Credit: Channarong Pherngjanda/shutterstock.com

Anatomy of the humerus quiz is an engaging way to assess your understanding of one of the most crucial bones in the human body. The humerus is the long bone located in the upper arm, extending from the shoulder to the elbow. Understanding its anatomy is essential for students in fields such as medicine, physical therapy, and sports science. This article provides an in-depth exploration of the humerus's anatomy, its functions, common injuries, and how to prepare for a quiz on this important subject.

Understanding the Humerus

The humerus is the largest bone in the upper limb, playing a vital role in arm movement and stability. It connects with various muscles, tendons, and ligaments, facilitating a wide range of motions.

Key Features of the Humerus

The humerus can be divided into three main sections:

- **Proximal End:** This part of the humerus connects to the shoulder. It features the head, neck, and greater and lesser tubercles.
- **Body (Diaphysis):** The long, cylindrical shaft of the bone that provides strength and support.
- **Distal End:** Located near the elbow joint, it includes the medial and lateral epicondyles, as well as the trochlea and capitulum.

Proximal End Anatomy

The proximal end of the humerus is crucial for shoulder joint mobility. Key anatomical features include:

1. **Head of the Humerus:** A smooth, rounded structure that fits into the glenoid cavity of the scapula, forming the shoulder joint.
2. **Greater Tubercle:** Located laterally, it serves as an attachment site for the rotator cuff muscles, including the supraspinatus, infraspinatus, and teres minor.
3. **Lesser Tubercle:** Positioned anteriorly, it is the attachment point for the subscapularis muscle.

4. Surgical Neck: The area just below the tubercles, often associated with fractures.

Distal End Anatomy

The distal end of the humerus plays a significant role in elbow function. Important components include:

- Trochlea: A spool-shaped structure that articulates with the ulna, allowing for flexion and extension of the elbow.
- Capitulum: A rounded surface that articulates with the radius, facilitating forearm rotation.
- Epicondyles: The medial and lateral epicondyles serve as attachment sites for muscles and ligaments that stabilize the elbow joint.

The Function of the Humerus

The humerus serves several important functions in the human body:

Movement

The humerus allows for a wide range of arm movements, including:

- Flexion and Extension: Bending and straightening the arm at the elbow.
- Abduction and Adduction: Moving the arm away from and towards the body at the shoulder joint.
- Internal and External Rotation: Rotating the arm inward and outward at the shoulder.

Support and Stability

The humerus provides a framework for muscle attachment and joint stability, allowing for coordinated movements during various activities, including lifting, throwing, and pushing.

Common Injuries Related to the Humerus

Understanding the anatomy of the humerus is crucial for recognizing potential injuries. Some common injuries include:

- **Fractures:** Humeral fractures can occur at the proximal end, surgical neck, or distal end, often resulting from falls or direct trauma.
- **Rotator Cuff Injuries:** Tears or inflammation of the rotator cuff muscles can lead to pain and limited mobility, often associated with repetitive overhead activities.
- **Epicondylitis:** Also known as tennis elbow (lateral epicondylitis) or golfer's elbow (medial epicondylitis), this condition results from overuse and strain on the tendons attached to the epicondyles.

Preparing for the Anatomy of the Humerus Quiz

To excel in an anatomy of the humerus quiz, it's essential to have a solid understanding of the bone's structure, functions, and associated injuries. Here are some effective study strategies:

1. Use Visual Aids

- Diagrams: Study labeled diagrams of the humerus to familiarize yourself with its anatomy.
- 3D Models: Utilize 3D anatomy software or physical models to visualize the humerus in relation to surrounding structures.

2. Practice Quizzes

- Online Resources: Take advantage of online quizzes and flashcards focused on the anatomy of the humerus.
- Group Study: Join a study group to quiz each other on different aspects of humeral anatomy.

3. Understand Clinical Relevance

- Case Studies: Review case studies that discuss injuries related to the humerus. Understanding real-world applications can enhance retention of anatomical knowledge.
- Clinical Terminology: Familiarize yourself with medical terminology related to the humerus, as it often appears in quiz questions.

4. Regular Review

- Consistent Study Schedule: Set aside regular time for review to reinforce your knowledge and memory of the humerus's anatomy.
- Summarize Information: Create summaries of key points related to the humerus to aid in quick recall during quizzes.

Conclusion

The anatomy of the humerus quiz serves as an excellent tool for gauging your understanding of this vital bone. By exploring the humerus's structure, functions, and common injuries, you can enhance your knowledge and prepare effectively for any assessment. Remember to utilize visual aids, practice quizzes, and clinical relevance to ensure a comprehensive understanding of humeral anatomy. With proper preparation, you'll be well on your way to acing your quiz and applying your knowledge in practical settings.

Frequently Asked Questions

What are the main parts of the humerus?

The main parts of the humerus include the head, greater tubercle, lesser tubercle, deltoid tuberosity, and the epicondyles.

Which part of the humerus articulates with the scapula?

The head of the humerus articulates with the glenoid cavity of the scapula.

What is the role of the greater and lesser tubercles of the humerus?

The greater and lesser tubercles serve as attachment points for muscles of the rotator cuff, which stabilize the shoulder joint.

Where is the deltoid tuberosity located on the humerus?

The deltoid tuberosity is located on the lateral aspect of the mid-shaft of the humerus and serves as an attachment point for the deltoid muscle.

What is the significance of the medial and lateral epicondyles of the humerus?

The medial and lateral epicondyles serve as attachment points for the forearm muscles and are important for elbow joint stability.

What is the distal end of the humerus and what features does it have?

The distal end of the humerus features the trochlea and capitulum, which articulate with the ulna and radius respectively at the elbow joint.

How can injuries to the humerus affect shoulder function?

Injuries to the humerus can affect shoulder function by disrupting the attachment of muscles, leading to decreased range of motion and strength in the shoulder joint.

Find other PDF article:

<https://soc.up.edu.ph/11-plot/pdf?dataid=WBD32-5225&title=candice-swanepoel-dating-history.pdf>

[Anatomy Of The Humerus Quiz](#)

1.68 - 52pojie.cn

Apr 24, 2022 · <https://pan ...>

2020 - 52pojie.cn

Mar 24, 2020 · 2020 app v2020.0.73 802M 4.X [hr] 2020 ...

human anatomy atlas - ...

Apr 14, 2020 · human anatomy atlas

52pojie.cn

Jun 2, 2021 · [] []

body Human Anatomy Atlas -

Nov 10, 2018 · visible body Human Anatomy Atlas 3D app ...

[Organon Anatomy](#) - [Organon](#) - [Anatomy](#)

Jul 25, 2019 · [Organon Anatomy](#) - [Organon](#) - [Anatomy](#) 3D [Organon Anatomy](#) - [Organon](#) - [Anatomy](#) ...

[Complete Anatomy windows](#) - [Complete Anatomy](#) - [52pojie.cn](#)

Apr 2, 2021 · [Complete Anatomy windows](#) - [Complete Anatomy](#) - [52pojie.cn](#) ... [Complete Anatomy windows](#) - [Complete Anatomy](#) - [52pojie.cn](#) ...

[Android - Complete Anatomy windows](#) - [Complete Anatomy](#) - [52pojie.cn](#)

Mar 21, 2016 · [Android - Complete Anatomy windows](#) - [Complete Anatomy](#) - [52pojie.cn](#) PC [Android - Complete Anatomy windows](#) - [Complete Anatomy](#) - [52pojie.cn](#) iPhone ...

[1.68](#) - [1.68](#) - [52pojie.cn](#)

Apr 24, 2022 · [1.68](#) - [1.68](#) - [52pojie.cn](#) [https://pan ...](#)

[2020](#) - [2020](#) - [52pojie.cn](#)

Mar 24, 2020 · [2020](#) - [2020](#) - [52pojie.cn](#) v2020.0.73 802M 4.X [hr] 2020 ...

[human anatomy atlas](#) - [human anatomy atlas](#) - [human anatomy atlas](#) ...

Apr 14, 2020 · [human anatomy atlas](#) - [human anatomy atlas](#) - [human anatomy atlas](#) ...

[body Human Anatomy Atlas](#) - [body Human Anatomy Atlas](#) - [body Human Anatomy Atlas](#) ...

Jun 2, 2021 · [body Human Anatomy Atlas](#) - [body Human Anatomy Atlas](#) - [body Human Anatomy Atlas](#) ...

[body Human Anatomy Atlas](#) - [body Human Anatomy Atlas](#) - [body Human Anatomy Atlas](#) ...

Nov 10, 2018 · [body Human Anatomy Atlas](#) - [body Human Anatomy Atlas](#) - [body Human Anatomy Atlas](#) app ...

[Organon Anatomy](#) - [Organon Anatomy](#) - [Organon Anatomy](#) ...

Jul 25, 2019 · [Organon Anatomy](#) - [Organon Anatomy](#) - [Organon Anatomy](#) 3D [Organon Anatomy](#) - [Organon Anatomy](#) - [Organon Anatomy](#) ...

[Complete Anatomy windows](#) - [Complete Anatomy windows](#) - [Complete Anatomy windows](#) ...

Apr 2, 2021 · [Complete Anatomy windows](#) - [Complete Anatomy windows](#) - [Complete Anatomy windows](#) ...

[Android - Complete Anatomy windows](#) - [Complete Anatomy windows](#) - [Complete Anatomy windows](#) ...

Mar 21, 2016 · [Android - Complete Anatomy windows](#) - [Complete Anatomy windows](#) - [Complete Anatomy windows](#) PC [Android - Complete Anatomy windows](#) - [Complete Anatomy windows](#) - [Complete Anatomy windows](#) iPhone ...

Test your knowledge with our engaging anatomy of the humerus quiz! Discover how well you know this vital bone and enhance your understanding. Learn more now!

[Back to Home](#)