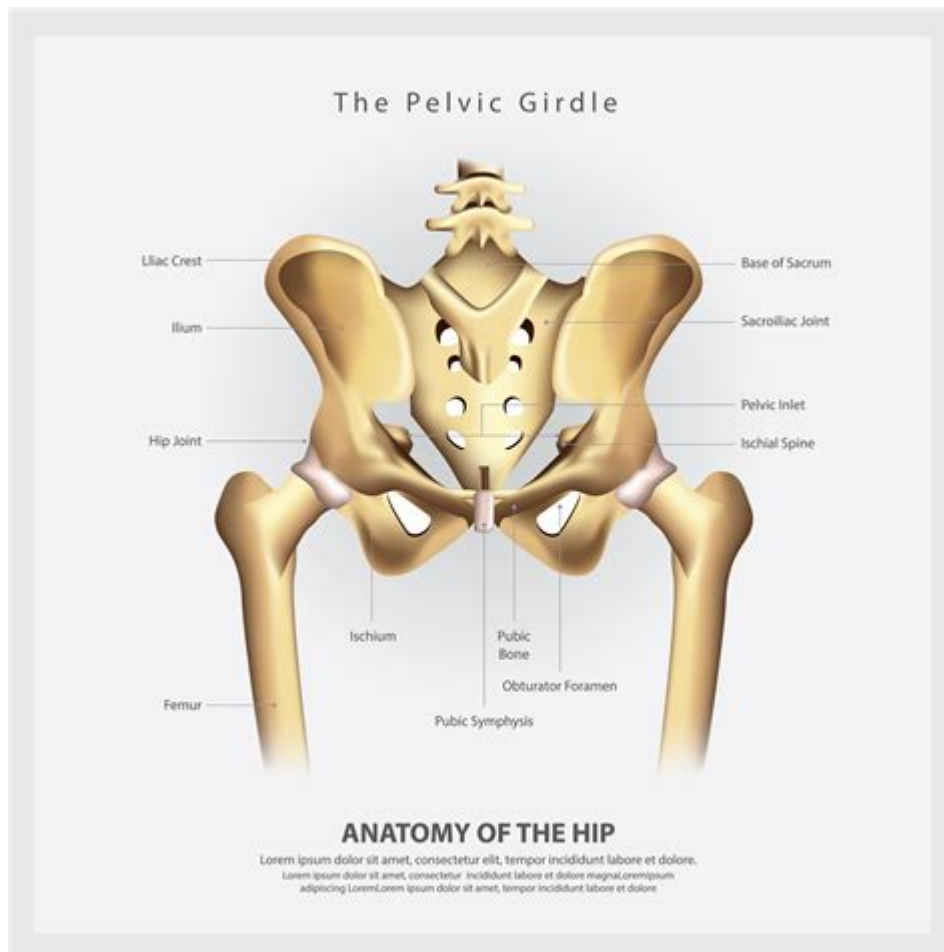


Anatomy Of The Pelvis And Hip



ANATOMY OF THE PELVIS AND HIP

THE PELVIS AND HIP ARE CRITICAL COMPONENTS OF THE HUMAN SKELETAL SYSTEM, PLAYING ESSENTIAL ROLES IN SUPPORTING THE BODY'S WEIGHT, FACILITATING MOVEMENT, AND PROTECTING VITAL ORGANS. UNDERSTANDING THE ANATOMY OF THE PELVIS AND HIP IS FUNDAMENTAL FOR MEDICAL PROFESSIONALS, ATHLETES, AND ANYONE INTERESTED IN HUMAN BIOLOGY. THIS ARTICLE WILL EXPLORE THE STRUCTURE, FUNCTION, AND SIGNIFICANCE OF THE PELVIS AND HIP, PROVIDING INSIGHT INTO THEIR ANATOMY AND THE COMMON INJURIES AND CONDITIONS ASSOCIATED WITH THESE REGIONS.

THE PELVIS: AN OVERVIEW

THE PELVIS IS A COMPLEX BONY STRUCTURE LOCATED AT THE LOWER END OF THE TRUNK. IT CONNECTS THE SPINE TO THE FEMURS (THIGH BONES) AND PROVIDES SUPPORT FOR THE ABDOMINAL ORGANS. THE PELVIS IS DIVIDED INTO TWO MAIN PARTS: THE GREATER (FALSE) PELVIS AND THE LESSER (TRUE) PELVIS.

STRUCTURE OF THE PELVIS

THE PELVIS CONSISTS OF SEVERAL BONES, WHICH CAN BE CATEGORIZED INTO THREE MAJOR COMPONENTS:

1. **ILIUM:** THE LARGEST PART OF THE PELVIS, FORMING THE UPPER PORTION. IT INCLUDES THE ILIAC CREST, WHICH CAN BE FELT ON THE SIDES OF THE HIPS.

2. ISCHIUM: THE LOWER, POSTERIOR PART OF THE PELVIS. IT SUPPORTS THE WEIGHT OF THE BODY WHEN SITTING.
3. PUBIS: THE FRONT PART OF THE PELVIS, WHICH JOINS WITH THE OTHER SIDE AT THE PUBIC SYMPHYSIS, A CARTILAGINOUS JOINT.

THESE THREE BONES FUSE TO FORM THE COXAL BONE (HIP BONE). THE PELVIS ALSO INCLUDES THE SACRUM AND COCCYX, WHICH ARE PART OF THE VERTEBRAL COLUMN. THE PELVIC INLET, A SPACE FORMED BY THE PELVIC BRIM, SEPARATES THE GREATER AND LESSER PELVIS, WHILE THE PELVIC OUTLET IS THE LOWER BORDER OF THE LESSER PELVIS.

FUNCTIONS OF THE PELVIS

THE PELVIS SERVES SEVERAL CRITICAL FUNCTIONS, INCLUDING:

- SUPPORT: IT BEARS THE WEIGHT OF THE UPPER BODY WHEN SITTING AND STANDING.
- MOVEMENT: THE PELVIS PROVIDES ATTACHMENT POINTS FOR MUSCLES THAT FACILITATE LOCOMOTION AND STABILITY.
- PROTECTION: IT ENCASES AND PROTECTS INTERNAL ORGANS SUCH AS THE BLADDER, REPRODUCTIVE ORGANS, AND PARTS OF THE GASTROINTESTINAL TRACT.
- CHILDBIRTH: IN FEMALES, THE PELVIS IS STRUCTURED TO ALLOW FOR THE PASSAGE OF A BABY DURING CHILDBIRTH.

THE HIP JOINT: STRUCTURE AND FUNCTION

THE HIP JOINT IS A BALL-AND-SOCKET JOINT THAT CONNECTS THE FEMUR TO THE PELVIS. IT IS ONE OF THE MOST MOBILE JOINTS IN THE HUMAN BODY, ALLOWING FOR A WIDE RANGE OF MOVEMENTS, INCLUDING FLEXION, EXTENSION, ABDUCTION, ADDUCTION, AND ROTATION.

COMPONENTS OF THE HIP JOINT

THE HIP JOINT COMPRISES SEVERAL KEY STRUCTURES:

1. ACETABULUM: A CUP-SHAPED SOCKET IN THE PELVIS WHERE THE FEMUR FITS. IT IS FORMED BY THE FUSION OF THE ILIUM, ISCHIUM, AND PUBIS.
2. FEMORAL HEAD: THE ROUNDED END OF THE FEMUR THAT FITS INTO THE ACETABULUM, FORMING THE BALL OF THE BALL-AND-SOCKET JOINT.
3. ARTICULAR CARTILAGE: A SMOOTH TISSUE THAT COVERS THE ACETABULUM AND THE FEMORAL HEAD, ALLOWING FOR FRICTIONLESS MOVEMENT.
4. JOINT CAPSULE: A FIBROUS STRUCTURE THAT SURROUNDS THE HIP JOINT, PROVIDING STABILITY AND CONTAINING SYNOVIAL FLUID, WHICH LUBRICATES THE JOINT.
5. LIGAMENTS: STRONG BANDS OF CONNECTIVE TISSUE THAT STABILIZE THE HIP JOINT. KEY LIGAMENTS INCLUDE:
 - ILIOFEMORAL LIGAMENT
 - ISCHIOFEMORAL LIGAMENT
 - PUBOFEMORAL LIGAMENT

FUNCTIONS OF THE HIP JOINT

THE HIP JOINT PLAYS A CRUCIAL ROLE IN:

- MOBILITY: IT ENABLES A WIDE RANGE OF MOVEMENTS NECESSARY FOR WALKING, RUNNING, AND CLIMBING.
- STABILITY: THE STRONG LIGAMENTS AND MUSCLES SURROUNDING THE HIP PROVIDE STABILITY, ALLOWING THE BODY TO MAINTAIN BALANCE DURING VARIOUS ACTIVITIES.
- WEIGHT BEARING: THE HIP JOINT HELPS DISTRIBUTE THE WEIGHT OF THE UPPER BODY TO THE LOWER LIMBS, ESPECIALLY DURING ACTIVITIES SUCH AS STANDING AND WALKING.

MUSCLE GROUPS ASSOCIATED WITH THE PELVIS AND HIP

SEVERAL MUSCLE GROUPS ARE ASSOCIATED WITH THE PELVIS AND HIP, CONTRIBUTING TO MOVEMENT AND STABILITY. THESE CAN BE CATEGORIZED INTO MAJOR MUSCLE GROUPS:

1. HIP FLEXORS

THE HIP FLEXORS ARE RESPONSIBLE FOR LIFTING THE THIGH TOWARDS THE ABDOMEN. KEY MUSCLES INCLUDE:

- ILIOPSOAS: COMPRISED OF THE PSOAS MAJOR AND ILIACUS MUSCLES.
- RECTUS FEMORIS: PART OF THE QUADRICEPS, IT ALSO AIDS IN KNEE EXTENSION.

2. HIP EXTENSORS

THESE MUSCLES ARE RESPONSIBLE FOR MOVING THE THIGH BACKWARD AND ARE ESSENTIAL FOR ACTIVITIES SUCH AS RUNNING AND STANDING. MAJOR MUSCLES INCLUDE:

- GLUTEUS MAXIMUS: THE LARGEST MUSCLE IN THE BUTTOCK, CRUCIAL FOR HIP EXTENSION.
- HAMSTRINGS: A GROUP OF MUSCLES LOCATED AT THE BACK OF THE THIGH (BICEPS FEMORIS, SEMITENDINOSUS, AND SEMIMEMBRANOSUS).

3. HIP ABDUCTORS

THESE MUSCLES MOVE THE THIGH AWAY FROM THE BODY'S MIDLINE AND ARE VITAL FOR MAINTAINING BALANCE. KEY MUSCLES INCLUDE:

- GLUTEUS MEDIUS: LOCATED ON THE OUTER SURFACE OF THE PELVIS.
- GLUTEUS MINIMUS: FOUND BENEATH THE GLUTEUS MEDIUS.

4. HIP ADDUCTORS

THESE MUSCLES BRING THE THIGH BACK TOWARDS THE MIDLINE. KEY MUSCLES INCLUDE:

- ADDUCTOR LONGUS
- ADDUCTOR BREVIS
- ADDUCTOR MAGNUS

5. ROTATORS

THESE MUSCLES ALLOW FOR ROTATION OF THE HIP JOINT AND INCLUDE:

- PIRIFORMIS
- OBTURATOR INTERNUS
- QUADRATUS FEMORIS

COMMON INJURIES AND CONDITIONS OF THE PELVIS AND HIP

THE PELVIS AND HIP ARE SUSCEPTIBLE TO VARIOUS INJURIES AND CONDITIONS, OFTEN RESULTING FROM TRAUMA, OVERUSE, OR DEGENERATIVE CHANGES. SOME COMMON ISSUES INCLUDE:

- FRACTURES: PELVIC FRACTURES CAN RESULT FROM FALLS OR ACCIDENTS, OFTEN REQUIRING SURGICAL INTERVENTION.
- HIP LABRAL TEARS: INJURIES TO THE CARTILAGE SURROUNDING THE HIP JOINT CAN CAUSE PAIN AND INSTABILITY.
- OSTEOARTHRITIS: DEGENERATION OF JOINT CARTILAGE OVER TIME CAN LEAD TO PAIN, STIFFNESS, AND REDUCED MOBILITY.
- BURSITIS: INFLAMMATION OF THE BURSAE (FLUID-FILLED SACS) AROUND THE HIP CAN CAUSE PAIN, PARTICULARLY WHEN LYING ON THE AFFECTED SIDE.
- TENDINOPATHY: OVERUSE INJURIES AFFECTING THE TENDONS AROUND THE HIP CAN LEAD TO PAIN AND IMPAIRED FUNCTION.

CONCLUSION

THE ANATOMY OF THE PELVIS AND HIP IS INTRICATE AND FUNDAMENTAL TO HUMAN MOVEMENT AND STABILITY. BY UNDERSTANDING THE STRUCTURE AND FUNCTION OF THESE VITAL COMPONENTS, INDIVIDUALS CAN BETTER APPRECIATE THEIR ROLES IN PHYSICAL ACTIVITY, INJURY PREVENTION, AND REHABILITATION. WHETHER IN THE CONTEXT OF SPORTS MEDICINE, PHYSICAL THERAPY, OR GENERAL HEALTH, KNOWLEDGE OF THE PELVIS AND HIP ANATOMY IS CRUCIAL FOR PROMOTING WELLNESS AND ENHANCING PERFORMANCE. THROUGH PROPER CARE AND ATTENTION TO THESE AREAS, WE CAN MAINTAIN MOBILITY AND QUALITY OF LIFE THROUGHOUT OUR LIVES.

FREQUENTLY ASKED QUESTIONS

WHAT ARE THE MAIN BONES THAT MAKE UP THE PELVIS?

THE MAIN BONES THAT MAKE UP THE PELVIS ARE THE ILIUM, ISCHIUM, PUBIS, SACRUM, AND COCCYX.

WHAT IS THE FUNCTION OF THE HIP JOINT?

THE HIP JOINT ALLOWS FOR A WIDE RANGE OF MOTION, CONNECTING THE FEMUR TO THE PELVIS AND SUPPORTING WEIGHT DURING ACTIVITIES LIKE WALKING, RUNNING, AND JUMPING.

HOW DOES THE ANATOMY OF THE PELVIS DIFFER BETWEEN MALES AND FEMALES?

THE FEMALE PELVIS IS GENERALLY WIDER AND HAS A LARGER PELVIC INLET AND OUTLET COMPARED TO THE MALE PELVIS, WHICH IS NARROWER AND MORE COMPACT, TO ACCOMMODATE CHILDBIRTH.

WHAT LIGAMENTS SUPPORT THE HIP JOINT?

THE MAIN LIGAMENTS THAT SUPPORT THE HIP JOINT INCLUDE THE ILIOFEMORAL LIGAMENT, ISCHIOFEMORAL LIGAMENT, AND PUBOFEMORAL LIGAMENT.

WHAT MUSCLES ARE PRIMARILY INVOLVED IN HIP MOVEMENT?

THE PRIMARY MUSCLES INVOLVED IN HIP MOVEMENT INCLUDE THE GLUTEUS MAXIMUS, GLUTEUS MEDIUS, ILIOPSOAS, QUADRICEPS, HAMSTRINGS, AND ADDUCTOR MUSCLES.

WHAT ROLE DOES THE ACETABULUM PLAY IN THE HIP JOINT?

THE ACETABULUM IS THE CUP-SHAPED SOCKET IN THE PELVIS THAT ARTICULATES WITH THE HEAD OF THE FEMUR, FORMING THE BALL-AND-SOCKET JOINT OF THE HIP.

WHAT ARE COMMON INJURIES ASSOCIATED WITH THE PELVIS AND HIP REGION?

COMMON INJURIES INCLUDE HIP FRACTURES, STRAINS, BURSITIS, AND LABRAL TEARS, OFTEN RESULTING FROM FALLS, OVERUSE, OR HIGH-IMPACT ACTIVITIES.

Find other PDF article:

<https://soc.up.edu.ph/02-word/files?ID=YLf02-7221&title=4th-grade-word-problem-worksheets.pdf>

Anatomy Of The Pelvis And Hip

1.68 - 52pojie.cn

Apr 24, 2022 · [https://pan ...](https://pan...)

2020 - 52pojie.cn

Mar 24, 2020 · 2020 app v2020.0.73 802M 4.X [hr] 2020 ...

human anatomy atlas - ...

Apr 14, 2020 · human anatomy atlas

1.68 - 52pojie.cn

Jun 2, 2021 · [] []

body Human Anatomy Atlas -

Nov 10, 2018 · visible body Human Anatomy Atlas 3D app

Organon Anatomy -

Jul 25, 2019 · 3D

Complete Anatomy windows - 52pojie.cn

Apr 2, 2021 · Complete Anatomy windows ... » 1 2 / 2

Android - 52pojie.cn

Mar 21, 2016 · PC iPhone

1.68 - 52pojie.cn

Apr 24, 2022 · [https://pan ...](https://pan...)

2020 - 52pojie.cn

Mar 24, 2020 · 2020 app v2020.0.73 802M 4.X [hr] 2020 ...

human anatomy atlas - ...

Apr 14, 2020 · [human anatomy atlas](#) [human anatomy atlas](#)

[body Human Anatomy Atlas](#) - [52pojie.cn](#)

Jun 2, 2021 · [\[PDF\] 3D Human Anatomy Atlas](#) [\[PDF\] 3D Human Anatomy Atlas](#)

[body Human Anatomy Atlas](#) - [52pojie.cn](#)

Nov 10, 2018 · visible body Human Anatomy Atlas [3D Human Anatomy Atlas](#) app [3D Human Anatomy Atlas](#) ...

[Organon Anatomy](#) - [52pojie.cn](#)

Jul 25, 2019 · [3D Human Anatomy Atlas](#) [3D Human Anatomy Atlas](#) ...

[Complete Anatomy windows](#) - [52pojie.cn](#)

Apr 2, 2021 · [Complete Anatomy windows](#) [\[PDF\] Complete Anatomy windows](#) ... [1 2 / 2](#) [1](#)

[Android - 52pojie.cn](#)

Mar 21, 2016 · [PC iPhone](#) [PC iPhone](#) ...

Explore the anatomy of the pelvis and hip in detail. Understand their structure

[Back to Home](#)