Anatomy Of The Airway Intubation

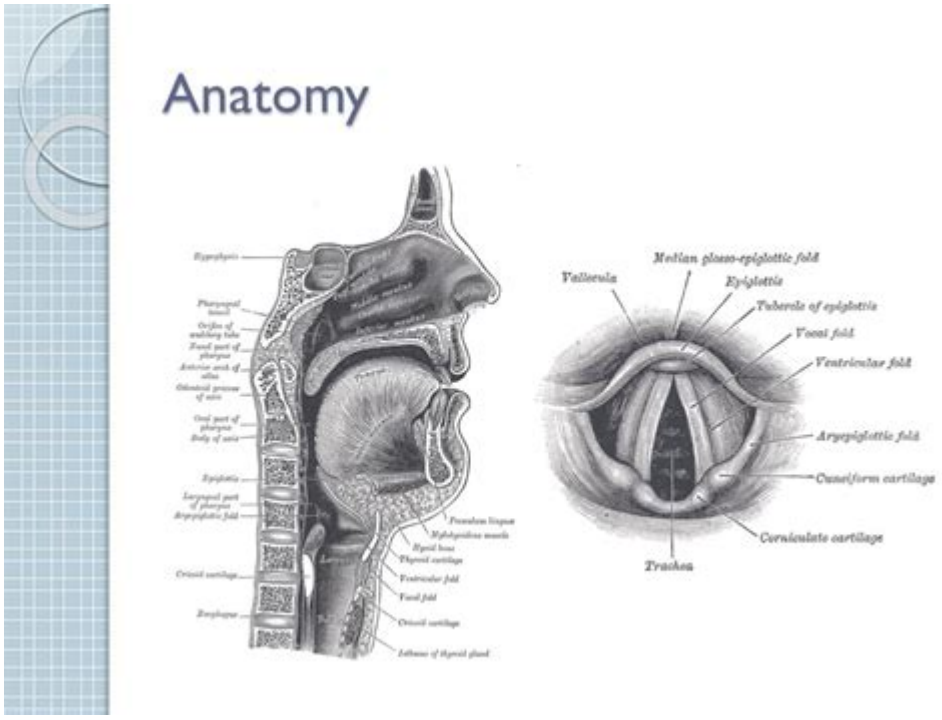

Anatomy of the airway intubation is a critical topic in the field of medicine, particularly in emergency medicine, anesthesiology, and critical care. Understanding the anatomy involved in airway management is essential for healthcare professionals to effectively secure the airway, especially in life-threatening situations. This article delves into the various anatomical structures, the techniques of intubation, and the considerations that must be taken into account during the intubation process.

Understanding Airway Anatomy

Airway anatomy encompasses several structures of the upper and lower respiratory tracts. These structures play crucial roles in the passage of air from the external environment to the lungs.

1. Upper Airway Structures

The upper airway is composed of several key structures that facilitate breathing and protect the lower airway from foreign materials.

- Nasal Cavity: The primary entry point for air, lined with mucous membranes that filter, warm, and humidify inhaled air.
- Pharynx: Divided into three sections:
- Nasopharynx: Extends from the nasal cavity to the soft palate.
- Oropharynx: Located between the soft palate and the epiglottis; the tongue's position plays a crucial role during intubation.
- Laryngopharynx: Extends from the epiglottis to the esophagus and larynx.

- Larynx: Contains the vocal cords and is responsible for sound production. It also has protective functions that prevent aspiration.

2. Lower Airway Structures

The lower airway includes structures that are involved in gas exchange and airway protection.

- Trachea: A rigid tube that extends from the larynx and bifurcates into the left and right bronchi. It is approximately 10-12 cm long in adults and is composed of C-shaped cartilage rings that maintain its structure.
- Bronchi: The left and right bronchi further divide into smaller bronchi and bronchioles within the lungs, leading to the alveoli where gas exchange occurs.

Indications for Intubation

Intubation is a procedure performed to secure an airway, and it is crucial to understand the indications that necessitate this intervention. Common indications include:

1. Respiratory Failure: Inability to maintain adequate oxygenation or ventilation.
2. Airway Protection: In patients with altered consciousness or risk of aspiration.
3. Surgical Procedures: General anesthesia requires intubation to facilitate controlled ventilation.
4. Severe Trauma: Head or neck trauma may compromise the airway.
5. Severe Obstruction: Conditions such as anaphylaxis or foreign body aspiration.

Techniques of Airway Intubation

There are several techniques used in airway intubation, with the choice of technique often based on the patient’s anatomy, condition, and the clinician's experience.

1. Oral Intubation

Oral intubation is the most common method used in emergency and surgical settings.

- Equipment Needed:
- Endotracheal tube (ET tube)
- Laryngoscope (with different blade sizes)
- Suction device
- Bag-valve mask (BVM) for pre-oxygenation
- Stylet (optional for rigidity)

- Procedure:
1. Pre-oxygenate the patient.
2. Position the patient: The sniffing position optimizes visualization.

3. Use the laryngoscope to visualize the vocal cords.
4. Insert the ET tube through the vocal cords into the trachea.
5. Inflate the cuff and secure the tube.

2. Nasotracheal Intubation

This technique is often used in conscious patients, particularly in cases of facial trauma.

- Equipment Needed:
- Endotracheal tube
- Laryngoscope or Magill forceps
- Lubricant

- Procedure:
1. Lubricate the ET tube.
2. Insert the tube through the nostril, guiding it down the nasal passage.
3. Continue until it reaches the oropharynx, where it can be guided into the trachea using a laryngoscope or Magill forceps.

3. Rapid Sequence Intubation (RSI)

RSI is a technique used for patients who are at high risk for aspiration or require immediate airway control.

- Steps Involved:
1. Pre-medication: Administer sedatives and paralytics.
2. Pre-oxygenation: Ensure the patient is well-oxygenated.
3. Positioning: Use the sniffing position.
4. Intubation: Perform the intubation as described in oral intubation.

Complications of Airway Intubation

While airway intubation is a life-saving procedure, it is not without risks. Complications can arise during or after the procedure, and understanding these is crucial for minimizing harm.

1. Immediate Complications

- Esophageal Intubation: Incorrect placement of the ET tube can lead to ventilation of the stomach rather than the lungs.
- Laryngeal Injury: Excessive force during intubation may result in damage to the vocal cords or larynx.
- Dental Damage: The use of a laryngoscope can inadvertently cause damage to the teeth.

2. Delayed Complications

- Tracheal Stenosis: Prolonged intubation may lead to narrowing of the trachea.
- Ventilator-associated pneumonia (VAP): Intubated patients are at high risk for developing pneumonia due to impaired airway defenses.

Monitoring and Confirmation of Tube Placement

After intubation, it is essential to confirm proper placement of the endotracheal tube. Several methods can be employed:

- Capnography: The presence of exhaled carbon dioxide (EtCO2) is a reliable indicator of correct placement.
- Auscultation: Listening for breath sounds over both lung fields and absence of sounds over the stomach.
- Chest X-ray: A radiographic confirmation can be performed to assess the tube’s position.

Conclusion

Understanding the anatomy of the airway intubation is fundamental for healthcare providers involved in airway management. Knowledge of the anatomical structures, indications for intubation, various techniques, potential complications, and methods for confirmation of tube placement is essential to ensure patient safety and effective airway management. As airway management continues to evolve, ongoing education and training remain critical for all healthcare professionals involved in this life-saving procedure.

Frequently Asked Questions

What is airway intubation and why is it performed?

Airway intubation is a medical procedure that involves placing a tube into the trachea to maintain an open airway, ensure adequate ventilation, and provide access for anesthesia or emergency interventions. It is commonly performed in critical situations such as respiratory failure or during surgical procedures.

What are the anatomical landmarks to consider during airway intubation?

Key anatomical landmarks include the oral cavity, pharynx, larynx, and trachea. Understanding the dimensions and locations of the epiglottis, vocal cords, and cricoid cartilage is crucial for successful intubation.

What are the different types of intubation techniques?

There are several intubation techniques, including orotracheal intubation (via the mouth), nasotracheal intubation (via the nose), and fiberoptic intubation. The choice of technique depends on the patient's condition and the clinical setting.

What are common complications associated with airway intubation?

Common complications can include trauma to the airway structures, esophageal intubation, aspiration of stomach contents, and injury to the teeth or vocal cords. Proper technique and equipment can minimize these risks.

How is correct placement of the endotracheal tube confirmed?

Correct placement is typically confirmed through methods such as visualization of the tube passing through the vocal cords, auscultation of breath sounds bilaterally, and the use of capnography to detect exhaled carbon dioxide.

What role does the larynx play in airway intubation?

The larynx, located at the upper part of the trachea, contains the vocal cords and acts as a protective mechanism for the airway. During intubation, proper identification and manipulation of the larynx are essential to ensure the endotracheal tube is correctly positioned.

What are the indications for emergency intubation?

Indications for emergency intubation include severe respiratory distress, inability to protect the airway due to decreased consciousness, significant trauma to the face or neck, and during resuscitation efforts in cardiac arrest.

Anatomy Of The Airway Intubation

求人体解剖学图谱 - 吾爱破解 - **52pojie.cn**
Jun 2, 2021 · [资源求助] 求人体解剖学图谱 [复制链接] 求人体解剖学图谱

人体解剖图谱（*body Human Anatomy Atlas*）安装 - 百度经验
Nov 10, 2018 · visible body Human Anatomy Atlas，3D人体解剖学图谱是美国波士顿的一家公司开发的人体构造解剖学图谱，通过这款app你可以详细了解人体的骨骼、内脏、血管等结构的 …

医学行业软件Organon Anatomy（我是搬运工） - 吾爱破解
Jul 25, 2019 · 我最近骨折 在医院里听病友说了一个软件可以模拟人类的骨骼进行活动，是3D效果。我向病友打听了这个软件。我在论坛里找到了相关的帖子，可是链接失效了 …

求**Complete Anatomy windows**版，谢谢 - 吾爱破解 - **52pojie.cn**
Apr 2, 2021 · 求Complete Anatomy windows版，谢谢 [复制链接] … 下一页 » 1 2 / 2 页 下一页

Android - 『精品软件区』 - 吾爱破解 - **52pojie.cn**
Mar 21, 2016 · 精品软件推荐，软件交流天地，汇集众多精彩评论，热心会员每日更新。找你所需要的，给你我分享的！这里不但有PC软件，安卓、iPhone等手机软件也统统包含。

人体解剖*1.68*版本自用 - 吾爱破解 - *52pojie.cn*
Apr 24, 2022 · 好多兄弟萌私信我要，今天打包了一下整合了四件套，分享给大家。没想到医学的兄弟萌这么多。直接上链接链接: https://pan …

2020人体解剖学图谱**app -** 吾爱破解 - **52pojie.cn**
Mar 24, 2020 · 名称: 2020人体解剖学图谱app破解版版本号: v2020.0.73 安卓内购版大小: 802M系统: 4.X及以上语言: 中文 [hr]简介: 2020人体解剖学图谱已付费完整版是专为解剖 …

医学 美术等人体有关的学生的福利 **human anatomy atlas**免费 - 吾 **…**
Apr 14, 2020 · 打开微软商店，搜索 human anatomy atlas 可以看到前面三个当中有两个是免费的，另外还有一个在打折。

求人体解剖学图谱 - 吾爱破解 - *52pojie.cn*
Jun 2, 2021 · [资源求助] 求人体解剖学图谱 [复制链接] 求人体解剖学图谱

人体解剖图谱（body Human Anatomy Atlas）安装 - 百度经验
Nov 10, 2018 · visible body Human Anatomy Atlas，3D人体解剖学图谱是美国波士顿的一家公司开发的人体构造解剖学图谱，通过这款app你可以详细了解人体的骨骼、内脏、血管等结构的详细构造，不管是不是从事医疗行业，大家都可以通过这款软件科普一下人体结构知识，如果对这 …

医学行业软件*Organon Anatomy*（我是搬运工） - 吾爱破解
Jul 25, 2019 · 我最近骨折 在医院里听病友说了一个软件可以模拟人类的骨骼进行活动，是3D效果。我向病友打听了这个软件。我在论坛里找到了相关的帖子，可是链接失效了。https://www.52 …

求Complete Anatomy windows版，谢谢 - 吾爱破解 - 52pojie.cn
Apr 2, 2021 · 求Complete Anatomy windows版，谢谢 [复制链接] … 下一页 » 1 2 / 2 页 下一页

Android - 『精品软件区』 - 吾爱破解 - 52pojie.cn
Mar 21, 2016 · 精品软件推荐，软件交流天地，汇集众多精彩评论，热心会员每日更新。找你所需要的，给你我分享的！这里不但有PC软件，安卓、iPhone等手机软件也统统包含。

Explore the anatomy of airway intubation in our detailed guide. Understand techniques

Back to Home