Anatomy Of Hand Wrist

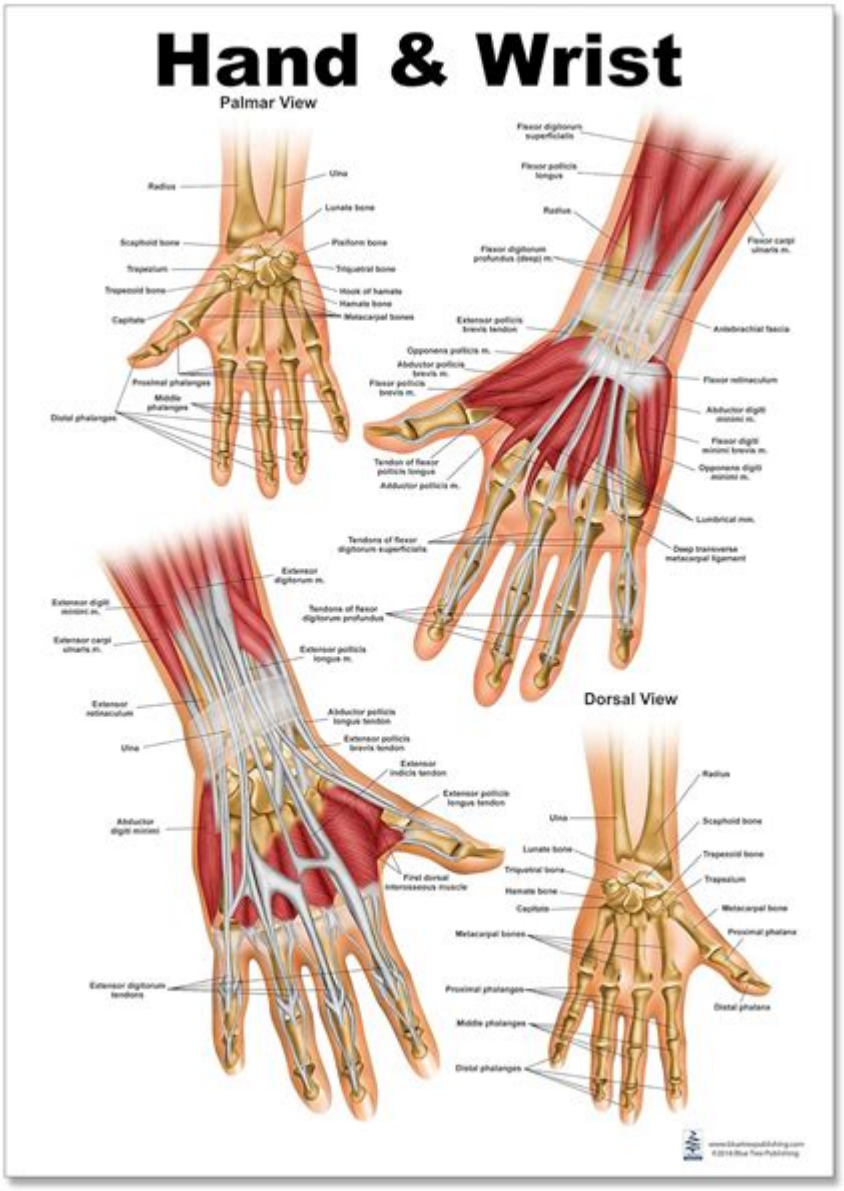

Anatomy of Hand Wrist is a complex and fascinating subject that plays a crucial role in our everyday activities. The hand and wrist are comprised of numerous bones, joints, muscles, tendons, and nerves that work together to provide a wide range of motion and functionality. Understanding the anatomy of the hand and wrist not only helps in appreciating the intricacies of human movement but also aids in diagnosing and treating injuries and conditions related to this critical part of the body.

Overview of the Hand and Wrist Anatomy

The anatomy of the hand and wrist can be divided into several components:

bones, joints, muscles, tendons, and nerves. Each of these components plays an essential role in the overall function of the hand and wrist.

Bones of the Hand and Wrist

The human hand consists of 27 bones, which can be categorized into three primary groups:

1. Carpal Bones: There are eight carpal bones that form the wrist. They are arranged in two rows:
- Proximal Row (from thumb to pinky): Scaphoid, Lunate, Triquetrum, Pisiform
- Distal Row (from thumb to pinky): Trapezium, Trapezoid, Capitate, Hamate

2. Metacarpal Bones: The five metacarpal bones connect the carpal bones to the fingers. Each metacarpal bone corresponds to one of the fingers and is numbered one to five, starting from the thumb.

3. Phalanges: The fingers contain a total of 14 phalanges:
- Each finger has three phalanges: proximal, middle, and distal.
- The thumb has two phalanges: proximal and distal.

Joints of the Hand and Wrist

The wrist and hand contain several important joints that allow for a wide range of motion:

- Wrist Joint: Formed by the articulation of the distal end of the radius and the carpal bones, allowing for flexion, extension, and slight rotation.

- Carpometacarpal Joints: The joints between the carpal bones and the metacarpals, particularly the thumb's carpometacarpal joint, which allows for opposability.

- Metacarpophalangeal Joints: These joints connect the metacarpal bones to the proximal phalanges, allowing for flexion, extension, abduction, and adduction.

- Interphalangeal Joints: The joints between the phalanges. Each finger has two interphalangeal joints (proximal and distal), while the thumb has one.

Muscles of the Hand and Wrist

The muscles of the hand and wrist can be categorized into two main groups: extrinsic muscles and intrinsic muscles.

Extrinsic Muscles

Extrinsic muscles originate in the forearm and insert into the hand. They are primarily responsible for the gross movements of the hand and wrist. These muscles can be further divided into flexors and extensors:

- Flexor Muscles: Located on the anterior side of the forearm, these muscles are responsible for flexing the wrist and fingers. Key flexors include:
- Flexor Carpi Radialis
- Flexor Carpi Ulnaris
- Flexor Digitorum Superficialis
- Flexor Digitorum Profundus
- Flexor Pollicis Longus

- Extensor Muscles: Located on the posterior side of the forearm, these muscles are responsible for extending the wrist and fingers. Key extensors include:
- Extensor Carpi Radialis Longus
- Extensor Carpi Radialis Brevis
- Extensor Carpi Ulnaris
- Extensor Digitorum
- Extensor Pollicis Longus and Brevis

Intrinsic Muscles

Intrinsic muscles are located within the hand itself and are responsible for fine motor skills and dexterity. These muscles can be categorized into three groups:

1. Thenar Muscles: Located at the base of the thumb, responsible for thumb movements:
- Abductor Pollicis Brevis
- Flexor Pollicis Brevis
- Opponens Pollicis
- Adductor Pollicis

2. Hypothenar Muscles: Located at the base of the little finger, responsible for its movements:
- Abductor Digiti Minimi
- Flexor Digiti Minimi Brevis
- Opponens Digiti Minimi

3. Lumbricals and Interossei: These muscles are responsible for the flexion and extension of the fingers and are essential for gripping and pinching:
- Lumbricals (four in total)
- Dorsal Interossei (four)
- Palmar Interossei (three)

Tendons and Ligaments

Tendons connect muscles to bones, while ligaments connect bones to other bones. Both are integral to the function and stability of the hand and wrist.

Tendons

The tendons of the hand and wrist facilitate movement. Key tendons include:

- Flexor Tendons: The flexor digitorum tendons run from the forearm muscles through the carpal tunnel to the fingers.

- Extensor Tendons: The extensor digitorum tendons extend from the forearm muscles and allow for finger extension.

Ligaments

Ligaments stabilize the wrist and hand. Key ligaments include:

- Radial Collateral Ligament: Provides stability on the thumb side of the wrist.
- Ulnar Collateral Ligament: Provides stability on the pinky side of the wrist.
- Palmar Radiocarpal Ligament: Supports the wrist during wrist flexion.

Nerves of the Hand and Wrist

The hand and wrist are innervated by several important nerves, primarily stemming from the brachial plexus:

- Median Nerve: Controls most of the flexor muscles in the forearm and provides sensation to the palm side of the thumb, index, middle, and part of the ring finger.
- Ulnar Nerve: Controls the intrinsic muscles of the hand and provides sensation to the little finger and part of the ring finger.
- Radial Nerve: Responsible for extending the wrist and fingers and provides sensation to the back of the hand and thumb.

Common Injuries and Conditions

Understanding the anatomy of the hand and wrist is essential for recognizing common injuries and conditions that affect this area, including:

- Carpal Tunnel Syndrome: Caused by compression of the median nerve, leading to pain, numbness, and weakness in the hand.
- Tendon Injuries: Such as tendonitis or ruptures, which can affect hand movement.
- Fractures: Commonly affecting the wrist (distal radius fractures) and fingers.
- Ligament Injuries: Such as sprains or tears, often resulting from falls or accidents.

Conclusion

In summary, the **anatomy of hand wrist** encompasses a complex interplay of bones, muscles, tendons, ligaments, and nerves that work together to provide functionality and dexterity. A thorough understanding of this anatomy is vital for healthcare professionals, athletes, and anyone interested in the mechanics of human movement. By gaining insights into the structure and function of the hand and wrist, we can better appreciate their significance in our daily lives and recognize the importance of taking care of these crucial body parts.

Frequently Asked Questions

What are the main bones in the human wrist?

The main bones in the human wrist include the radius, ulna, and eight carpal bones: scaphoid, lunate, triquetrum, pisiform, trapezium, trapezoid, capitate, and hamate.

What is the function of the carpal bones?

The carpal bones provide flexibility and stability to the wrist joint, allowing for a wide range of motion and helping to support hand movements.

How many muscles are involved in the movement of the hand and wrist?

There are over 30 muscles that control the movements of the hand and wrist, including intrinsic muscles located within the hand and extrinsic muscles originating in the forearm.

What is the significance of the flexor and extensor tendons in the hand?

Flexor tendons allow for the bending of the fingers, while extensor tendons enable the straightening of the fingers. Together, they facilitate grip and fine motor skills.

What are the common injuries associated with the wrist?

Common wrist injuries include sprains, fractures (especially of the scaphoid), tendonitis, and carpal tunnel syndrome.

What is carpal tunnel syndrome?

Carpal tunnel syndrome is a condition caused by compression of the median nerve as it travels through the wrist, leading to pain, numbness, and weakness in the hand.

How does the anatomy of the wrist contribute to its range of motion?

The complex arrangement of the carpal bones, along with the flexibility of ligaments and the presence of synovial fluid, allows the wrist to perform various movements such as flexion, extension, and rotation.

What role do ligaments play in the stability of the wrist?

Ligaments connect bones to each other, providing stability to the wrist joint and preventing excessive movements that could lead to injuries.

What are the potential effects of repetitive wrist

movements?

Repetitive wrist movements can lead to overuse injuries, such as tendonitis or carpal tunnel syndrome, resulting in pain and decreased function.

How is the anatomy of the hand and wrist adapted for fine motor skills?

The intricate arrangement of bones, muscles, and tendons, along with a high density of sensory receptors in the fingers, allows for precise and coordinated movements essential for fine motor skills.

Anatomy Of Hand Wrist

人体解剖1.68版本自用 - 吾爱破解 - 52pojie.cn
Apr 24, 2022 · 好多兄弟萌私信我要，今天打包了一下整合了四件套，分享给大家。没想到医学的兄弟萌这么多。直接上链接链接: https://pan ...

*2020*人体解剖学图谱*app - 吾爱破解 - 52pojie.cn*
Mar 24, 2020 · 名称: 2020人体解剖学图谱app破解版版本号: v2020.0.73 安卓内购版大小: 802M系统: 4.X及以上语言: 中文 [hr]简介: 2020人体解剖学图谱已付费完整版是专为解剖 ...

医学 美术等人体有关的学生的福利 **human anatomy atlas**免费 **- 吾 ...**
Apr 14, 2020 · 打开微软商店，搜索 human anatomy atlas 可以看到前面三个当中有两个是免费的，另外还有一个在打折。

求人体解剖学图谱 **- 吾爱破解 - 52pojie.cn**
Jun 2, 2021 · [资源求助] 求人体解剖学图谱 [复制链接] 求人体解剖学图谱

人体解剖图谱（body Human Anatomy Atlas）安装 - 百度经验
Nov 10, 2018 · visible body Human Anatomy Atlas，3D人体解剖学图谱是美国波士顿的一家公司开发的人体构造解剖学图谱，通过这款app你可以详细了解人体的骨骼、内脏、血管等结构的 ...

医学行业软件Organon Anatomy（我是搬运工） - 吾爱破解
Jul 25, 2019 · 我最近骨折 在医院里听病友说了一个软件可以模拟人类的骨骼进行活动，是3D效果。我向病友打听了这个软件。我在论坛里找到了相关的帖子，可是链接失效了 ...

求**Complete Anatomy windows**版，谢谢 **- 吾爱破解 - 52pojie.cn**
Apr 2, 2021 · 求Complete Anatomy windows版，谢谢 [复制链接] ... 下一页 » 1 2 / 2 页 下一页

Android - 『精品软件区』 - 吾爱破解 - 52pojie.cn
Mar 21, 2016 · 精品软件推荐，软件交流天地，汇集众多精彩评论，热心会员每日更新。找你所需要的，给你我分享的！这里不但有PC软件，安卓、iPhone等手机软件也统统包含。

人体解剖**1.68**版本自用 **- 吾爱破解 - 52pojie.cn**

Apr 24, 2022 · □□□https://pan …

2020□□□□□□□app - □□□□ - 52pojie.cn
Mar 24, 2020 · □□□2020□□□□□□□app□□□□□□□v2020.0.73 □□□□□□□□802M□□□4.X□□□□□□□□ [hr]□□□2020□□□□□□□□□□□□□□□□□□□ …

□□ □□□□□□□□□□□□□□ human anatomy atlas□□ - □ …
Apr 14, 2020 · □□□□□□□□□ human anatomy atlas □□□□□□□□□□□□□□□□□□□□□□□□□□□□

□□□□□□□□ - □□□□ - 52pojie.cn
Jun 2, 2021 · [□□□□] □□□□□□□□ [□□□□] □□□□□□□□

□□□□□□□body Human Anatomy Atlas□□□ - □□□□
Nov 10, 2018 · visible body Human Anatomy Atlas □3D□□□□□□□□□□□□□□□□□□□□□□□□□□□□□□□□□□□□app□□□□□□□□□□□□□□□□□□□□□□ …

□□□□□□*Organon Anatomy*□ □□□□□□ - □□□□
Jul 25, 2019 · □□□□□ □□□□□□□□□□□□□□□□□□□□□□□□□□□□□3D□□□□□□□□□□□□□□□□□□□□□□□□□□□□□□□□□□□□□□□ …

□*Complete Anatomy windows*□□□□ - □□□□ - *52pojie.cn*
Apr 2, 2021 · □Complete Anatomy windows□□□□ [□□□□] … □□□ » 1 2 / 2 □ □□□

Android - □□□□□□□ - □□□□ - *52pojie.cn*
Mar 21, 2016 · □□□PC□□□□□□iPhone□□□□□□□□□□□□

Explore the intricate anatomy of the hand and wrist

Back to Home