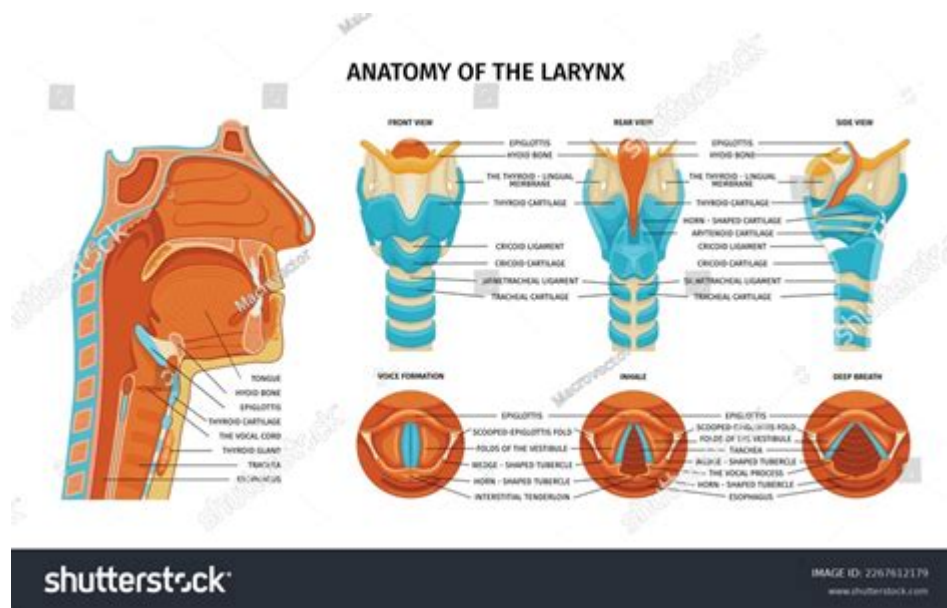


Anatomy Of The Larynx Labeled



Anatomy of the larynx is a fascinating subject that encompasses the structure and function of a vital organ in the human body. The larynx, commonly referred to as the voice box, plays a crucial role in respiration, phonation, and protecting the airway during swallowing. Understanding the anatomy of the larynx provides insights into its complex workings and its importance in both speaking and breathing. This article will explore the detailed anatomy of the larynx, including its structure, components, functions, and clinical significance.

Overview of the Larynx

The larynx is situated in the neck, between the pharynx and the trachea. It is typically located at the level of the fourth to sixth cervical vertebrae (C4-C6) in adults. The larynx is a cartilaginous structure composed of several cartilages, ligaments, muscles, and membranes that work together to facilitate its functions.

Primary Functions of the Larynx

The larynx serves several essential functions:

1. **Voice Production:** The larynx contains the vocal cords (or vocal folds), which vibrate to produce sound when air is expelled from the lungs.
2. **Airway Protection:** During swallowing, the larynx moves upward, and a flap known as the epiglottis covers the opening to the trachea, preventing food and liquid from entering the airway.

3. Respiration: The larynx acts as a passage for air to enter the trachea and lungs.
4. Cough Reflex: The larynx contains sensory receptors that trigger a cough reflex when foreign particles enter the airway.

Anatomical Components of the Larynx

The larynx is made up of several significant components, primarily cartilages, muscles, and membranes.

Cartilages of the Larynx

The larynx consists of nine cartilages divided into three paired and three unpaired cartilages:

1. Unpaired Cartilages:

- Thyroid Cartilage: The largest cartilage, forming the anterior wall of the larynx. It is often referred to as the "Adam's apple."
- Cricoid Cartilage: A complete ring of cartilage located below the thyroid cartilage, providing structural support.
- Epiglottis: A leaf-shaped flap of cartilage that covers the laryngeal inlet during swallowing.

2. Paired Cartilages:

- Arytenoid Cartilages: Two small cartilages that play a crucial role in vocal cord movement and tension regulation.
- Corniculate Cartilages: Two small, horn-like structures that sit atop the arytenoid cartilages.
- Cuneiform Cartilages: Small, rod-like structures located within the aryepiglottic fold that provide support to the laryngeal tissue.

Muscles of the Larynx

The laryngeal muscles are categorized into two groups: intrinsic and extrinsic muscles.

1. Intrinsic Muscles: These muscles are responsible for controlling the tension and position of the vocal cords. They include:

- Cricothyroid Muscles:
- Posterior Cricothyroid: Opens the vocal cords.
- Lateral Cricothyroid: Closes the vocal cords.
- Thyroarytenoid Muscle: Adjusts the tension of the vocal cords.
- Arytenoid Muscles: Help in adduction of the vocal cords during phonation.

2. Extrinsic Muscles: These muscles support the larynx and assist in its

movement. They include:

- Suprahyoid Muscles: Elevate the larynx during swallowing (e.g., digastric, mylohyoid).
- Infrahyoid Muscles: Depress the larynx after swallowing (e.g., sternohyoid, omohyoid).

Membranes and Ligaments of the Larynx

Several membranes and ligaments provide structural support and flexibility to the larynx:

- Thyrohyoid Membrane: Connects the thyroid cartilage to the hyoid bone.
- Cricothyroid Ligament: Connects the cricoid cartilage to the thyroid cartilage, important for voice modulation.
- Vestibular Ligaments: Support the false vocal cords (vestibular folds).
- Vocal Ligaments: Form the core of the true vocal cords (vocal folds), essential for sound production.

Vocal Cords and Sound Production

The vocal cords are pivotal in the process of phonation. They are located within the larynx and consist of multiple layers:

1. Epithelium: The outermost layer that protects the vocal cords.
2. Lamina Propria: Comprising three layers (superficial, intermediate, and deep), this layer influences the pliability and tension of the vocal cords.
3. Vocalis Muscle: The innermost layer that adjusts the tension of the vocal cords.

Mechanism of Sound Production

The process of sound production can be summarized as follows:

1. Airflow Initiation: Air is pushed from the lungs through the trachea into the larynx.
2. Vocal Cord Vibration: The airflow causes the vocal cords to open and close rapidly, producing sound waves.
3. Resonance: The sound waves travel through the vocal tract, where they are modified by the throat, mouth, and nasal cavities, resulting in various pitches and tones.

Clinical Significance of the Larynx

Understanding the anatomy of the larynx is crucial for diagnosing and treating various conditions that can affect its function.

Common Laryngeal Disorders

1. Laryngitis: Inflammation of the larynx, often resulting in hoarseness or loss of voice.
2. Vocal Cord Nodules: Benign growths on the vocal cords due to overuse or misuse, affecting voice quality.
3. Laryngeal Cancer: Malignant tumors can develop in the larynx, leading to symptoms such as persistent hoarseness and difficulty swallowing.
4. Laryngeal Trauma: Injuries to the larynx can occur due to accidents or surgical procedures, impacting airway function.

Diagnostic Procedures

Several diagnostic procedures are used to assess laryngeal health, including:

- Laryngoscopy: A procedure that uses a laryngoscope to visualize the larynx.
- Videostroboscopy: A specialized examination that allows for the observation of vocal cord vibration and function.
- Biopsy: A procedure to remove a sample of tissue for analysis, often performed when cancer is suspected.

Treatment Options

Treatment for laryngeal disorders may vary based on the underlying condition and severity:

- Voice Therapy: Often recommended for vocal cord nodules or laryngitis to promote proper vocal habits.
- Surgery: May be necessary to remove growths, tumors, or repair structural issues.
- Medications: Anti-inflammatory drugs or antibiotics may be prescribed as needed to manage infections or inflammation.

Conclusion

The anatomy of the larynx is intricate and essential for various functions, including voice production, airway protection, and breathing. Understanding

the laryngeal structure, including its cartilages, muscles, and ligaments, provides a foundation for recognizing the significance of the larynx in health and disease. As a vital component of the respiratory and vocal systems, the larynx requires careful attention and management to maintain its proper function and support overall well-being.

Frequently Asked Questions

What are the main components of the larynx?

The main components of the larynx include the thyroid cartilage, cricoid cartilage, arytenoid cartilages, epiglottis, and vocal cords.

How does the larynx contribute to phonation?

The larynx houses the vocal cords, which vibrate to produce sound when air passes through them, allowing for phonation.

What is the function of the epiglottis in the larynx?

The epiglottis acts as a flap that covers the trachea during swallowing, preventing food and liquid from entering the airway.

What is the anatomical location of the larynx?

The larynx is located in the neck, situated between the pharynx and the trachea, typically at the level of the fourth to sixth cervical vertebrae.

What role does the larynx play in breathing?

The larynx acts as a passageway for air to enter the trachea and lungs while also regulating airflow and protecting the airway during swallowing.

What are the differences between the true vocal cords and false vocal cords?

True vocal cords (vocal folds) are involved in sound production, while false vocal cords (vestibular folds) do not produce sound but help protect the airway.

What are some common disorders associated with the larynx?

Common disorders include laryngitis, vocal cord nodules, laryngeal cancer, and laryngeal paralysis.

How can the anatomy of the larynx be visualized for medical study?

The anatomy of the larynx can be visualized through imaging techniques such as laryngoscopy, CT scans, or MRI, often supplemented with labeled diagrams.

Find other PDF article:

<https://soc.up.edu.ph/37-lead/Book?dataid=pTW41-9009&title=life-span-development-18th-edition-e-book.pdf>

Anatomy Of The Larynx Labeled

1.68 - 52pojie.cn

Apr 24, 2022 · <https://pan ...>

2020 app - 52pojie.cn

Mar 24, 2020 · 2020 app v2020.0.73 802M 4.X [hr] 2020 ...

human anatomy atlas - ...

Apr 14, 2020 · human anatomy atlas

- 52pojie.cn

Jun 2, 2021 · [] []

body Human Anatomy Atlas -

Nov 10, 2018 · visible body Human Anatomy Atlas 3D app

Organon Anatomy -

Jul 25, 2019 · 3D

Complete Anatomy windows - 52pojie.cn

Apr 2, 2021 · Complete Anatomy windows [] ... » 1 2 / 2

Android - 52pojie.cn

Mar 21, 2016 · PC iPhone

1.68 - 52pojie.cn

Apr 24, 2022 · <https://pan ...>

2020 app - 52pojie.cn

Mar 24, 2020 · 2020 app v2020.0.73 802M 4.X [hr] 2020

anatomy of the larynx labeled ...

[human anatomy atlas](#) - ...

Apr 14, 2020 · human anatomy atlas

- 52pojie.cn

Jun 2, 2021 · [] []

body Human Anatomy Atlas -

Nov 10, 2018 · visible body Human Anatomy Atlas 3D app

[Organon Anatomy](#) -

Jul 25, 2019 · 3D

[Complete Anatomy windows](#) - 52pojie.cn

Apr 2, 2021 · Complete Anatomy windows [] ... » 1 2 / 2

[Android](#) - 52pojie.cn

Mar 21, 2016 · PC iPhone

Explore the detailed anatomy of the larynx labeled in this informative article. Discover how each part functions and its importance in voice production. Learn more!

[Back to Home](#)