Anatomy Of Lower Leg Nerves

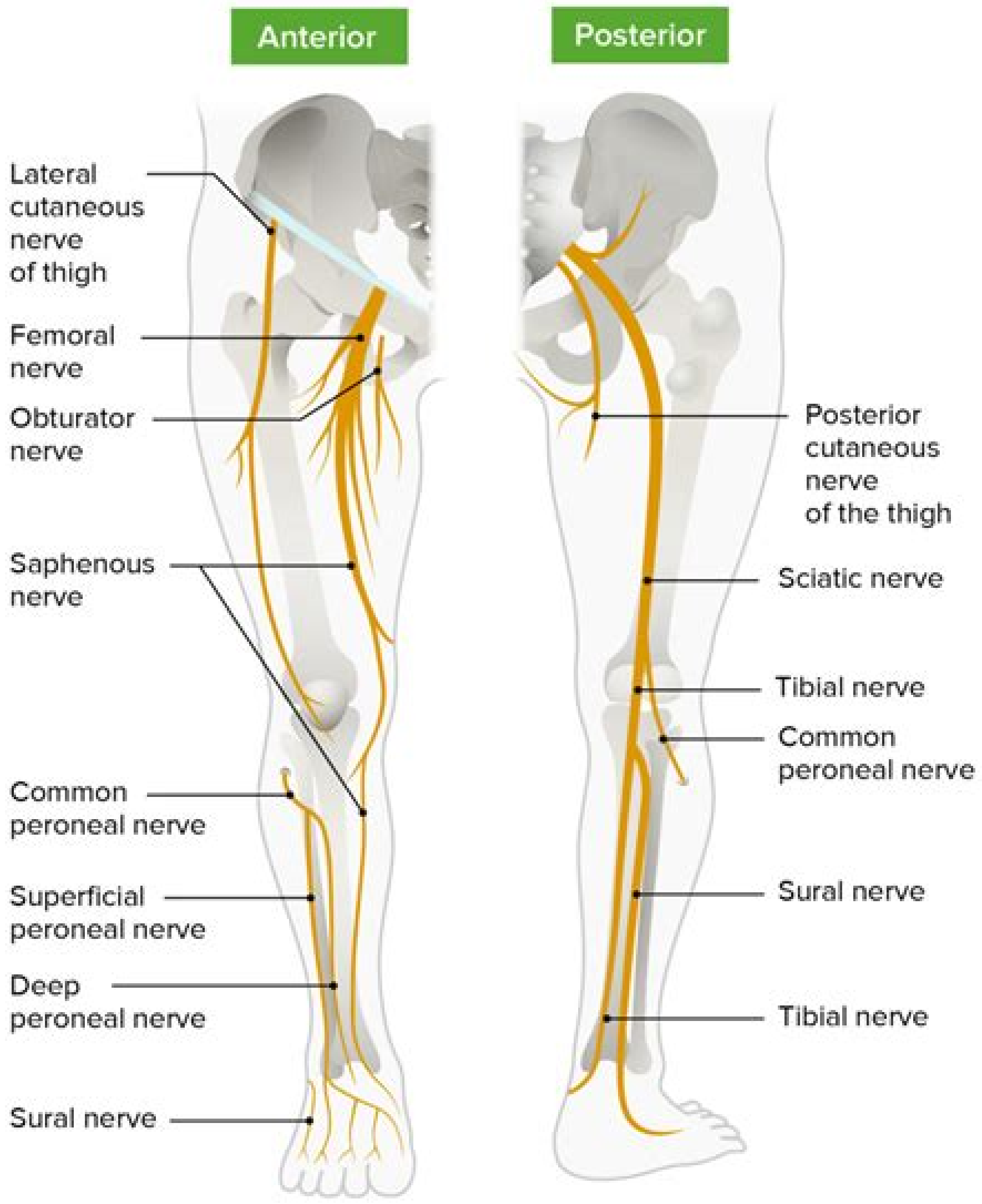

Anatomy of lower leg nerves plays a crucial role in the functioning of the lower extremity, affecting motor control, sensation, and overall mobility. Understanding the complex network of nerves in the lower leg is essential for diagnosing and treating a variety of conditions that can impact movement and sensation. This article will delve into the anatomy of lower leg nerves, detailing their origin, pathways, functions, and clinical relevance.

Overview of the Nervous System in the Lower Leg

The nervous system of the lower leg is primarily composed of peripheral nerves, which branch out from the spinal cord and innervate muscles and skin. The lower leg is supplied by three main nerves:

1. Tibial Nerve

2. Common Peroneal Nerve
3. Saphenous Nerve

These nerves are responsible for motor and sensory functions, facilitating movement and providing sensation to the skin.

The Tibial Nerve

Origin and Pathway

The tibial nerve is one of the two primary branches of the sciatic nerve. It originates from the lumbosacral plexus (L4-S3) and travels down the back of the thigh, passing through the popliteal fossa (the area behind the knee). It then enters the leg, running down the posterior compartment.

- Anatomical Locations:
- Popliteal Fossa: The tibial nerve is located at the posterior aspect of the knee.
- Flexor Compartment: It innervates muscles in the posterior compartment of the leg, including the gastrocnemius, soleus, and tibialis posterior.

Functions

The tibial nerve has several important functions:

- Motor Functions: It innervates the muscles responsible for plantarflexion (pointing the toes) and inversion of the foot.
- Sensory Functions: It provides sensation to the skin on the sole of the foot and the heel through its terminal branches, the medial and lateral plantar nerves.

Clinical Relevance

Damage or compression of the tibial nerve can lead to:

- Tarsal Tunnel Syndrome: A condition where the tibial nerve is compressed as it passes through the tarsal tunnel, leading to pain and numbness in the foot.
- Plantar Fasciitis: While primarily a foot condition, altered function due to tibial nerve issues can exacerbate symptoms.

The Common Peroneal Nerve

Origin and Pathway

The common peroneal nerve, also a branch of the sciatic nerve, diverges from the tibial nerve in the popliteal fossa. It travels laterally around the neck of the fibula, where it is susceptible to injury due to its superficial position.

- Anatomical Locations:
- Fibular Head: The nerve wraps around the fibular head before branching into two main divisions: the superficial peroneal nerve and the deep peroneal nerve.

Functions

The common peroneal nerve is responsible for:

- Motor Functions:
- Superficial Peroneal Nerve: Innervates the lateral compartment muscles, including the peroneus longus and peroneus brevis, which facilitate foot eversion.
- Deep Peroneal Nerve: Innervates the anterior compartment muscles, including the tibialis anterior, which is crucial for dorsiflexion (lifting the foot).

- Sensory Functions:
- The superficial peroneal nerve provides sensation to the dorsum of the foot and the lower lateral leg.
- The deep peroneal nerve supplies sensation between the first and second toes.

Clinical Relevance

Common peroneal nerve injury can lead to:

- Foot Drop: Inability to dorsiflex the foot, resulting in dragging of the toes during walking.
- Sensory Loss: Numbness in the dorsum of the foot and lateral aspect of the lower leg.

The Saphenous Nerve

Origin and Pathway

The saphenous nerve is a branch of the femoral nerve (L2-L4) and is the longest cutaneous branch of the femoral nerve. It provides sensory innervation to the medial side of the leg and foot.

- Anatomical Locations:
- Adductor Canal: The saphenous nerve travels through this canal before emerging at the medial aspect of the knee.

Functions

The primary function of the saphenous nerve is sensory:

- Sensory Functions: It provides sensation to the skin on the medial aspect of the leg and the foot, extending to the medial malleolus.

Clinical Relevance

The saphenous nerve can be affected by:

- Saphenous Nerve Neuralgia: Pain or discomfort along the distribution of the nerve, often related to trauma or surgical procedures.
- Varicose Veins: Increased pressure on the saphenous nerve can lead to discomfort in patients with varicose veins.

Common Pathologies Involving Lower Leg Nerves

Several conditions can affect the nerves of the lower leg, leading to a range of symptoms, including pain, weakness, and sensory deficits.

Neuropathies

Peripheral neuropathies can arise from various causes, including:

- Diabetes: Diabetic neuropathy can affect sensation and motor function in the lower legs.
- Alcoholism: Nutritional deficiencies associated with chronic alcoholism can

lead to peripheral neuropathies.
- Infections: Viral or bacterial infections can damage nerves, leading to neuropathic symptoms.

Trauma

Injuries to the lower leg can directly impact nerve function:

- Direct Compression: Fractures of the fibula or trauma to the knee can compress the common peroneal nerve.
- Surgical Complications: Surgical procedures in the area can inadvertently damage nerves.

Entrapment Syndromes

Nerve entrapment syndromes occur when a nerve is compressed by surrounding structures:

- Tarsal Tunnel Syndrome: As mentioned earlier, this condition affects the tibial nerve at the ankle.
- Common Peroneal Nerve Palsy: Compression at the fibular head can lead to foot drop and sensory loss.

Conclusion

The anatomy of lower leg nerves is intricate, with each nerve playing a vital role in motor control and sensory feedback. Understanding the pathways, functions, and potential pathologies associated with the tibial, common peroneal, and saphenous nerves is essential for healthcare professionals. Accurate diagnosis and effective treatment of nerve-related conditions can significantly enhance the quality of life for those affected. Future research and advancements in medical technology may continue to improve our understanding of these vital structures, leading to better therapeutic approaches for lower leg nerve injuries and disorders.

Frequently Asked Questions

What are the major nerves of the lower leg?

The major nerves of the lower leg include the tibial nerve, common peroneal nerve (fibular nerve), and sural nerve.

What is the function of the tibial nerve?

The tibial nerve is responsible for innervating the muscles of the posterior compartment of the leg and providing sensation to the sole of the foot.

How does the common peroneal nerve contribute to foot movement?

The common peroneal nerve innervates the muscles responsible for dorsiflexion and eversion of the foot, primarily the tibialis anterior and fibularis muscles.

What are common injuries affecting lower leg nerves?

Common injuries include peroneal nerve palsy, which can occur due to compression or trauma, leading to foot drop and loss of sensation on the dorsum of the foot.

How can nerve entrapment syndromes affect the lower leg?

Nerve entrapment syndromes, such as tarsal tunnel syndrome, can lead to pain, tingling, and numbness in the lower leg and foot due to compression of the tibial nerve.

What diagnostic tools are used to assess lower leg nerve function?

Diagnostic tools include electromyography (EMG), nerve conduction studies, and imaging techniques like MRI to evaluate nerve compression or injury.

Find other PDF article:
https://soc.up.edu.ph/49-flash/Book?ID=aFH51-7849&title=q-skills-for-success-listening-and-speaking-1-teachers-book.pdf

[Anatomy Of Lower Leg Nerves]()

□□□□1.68□□□□ - □□□□ - 52pojie.cn
Apr 24, 2022 · □□https://pan ...

2020□□□□□□□app - □□□□ - 52pojie.cn
Mar 24, 2020 · □□□2020□□□□□□□app□□□□□□□v2020.0.73 □□□□□□□□802M□□□4.X□□□□□□□□ [hr]□□□2020 □□□□□□□□□□□□□□□□□□ ...

□□ □□□□□□□□□□□□□□ human anatomy atlas□□ - □ ...

Apr 14, 2020 · 打开微软商店，搜索 human anatomy atlas 可以看到前面三个当中有两个是免费的，另外还有一个在打折。

求人体解剖学图谱 - 吾爱破解 - **52pojie.cn**
Jun 2, 2021 · [资源求助] 求人体解剖学图谱 [复制链接] 求人体解剖学图谱

人体解剖图谱（body Human Anatomy Atlas）安装 - 百度经验
Nov 10, 2018 · visible body Human Anatomy Atlas，3D人体解剖学图谱是美国波士顿的一家公司开发的人体构造解剖学图谱，通过这款app你可以详细了解人体的骨骼、内脏、血管等结构的 …

医学行业软件**Organon Anatomy**（我是搬运工） - 吾爱破解
Jul 25, 2019 · 我最近骨折 在医院里听病友说了一个软件可以模拟人类的骨骼进行活动，是3D效果。我向病友打听了这个软件。我在论坛里找到了相关的帖子，可是链接失效了 …

求Complete Anatomy windows版，谢谢 - 吾爱破解 - 52pojie.cn
Apr 2, 2021 · 求Complete Anatomy windows版，谢谢 [复制链接] … 下一页 » 1 2 / 2 页 下一页

Android - 『精品软件区』 - 吾爱破解 **- 52pojie.cn**
Mar 21, 2016 · 精品软件推荐，软件交流天地，汇集众多精彩评论，热心会员每日更新。找你所需要的，给你我分享的！这里不但有PC软件，安卓、iPhone等手机软件也统统包含。

人体解剖**1.68**版本自用 - 吾爱破解 **- 52pojie.cn**
Apr 24, 2022 · 好多兄弟萌私信我要，今天打包了一下整合了四件套，分享给大家。没想到医学的兄弟萌这么多。直接上链接链接: https://pan …

2020人体解剖学图谱app - 吾爱破解 - 52pojie.cn
Mar 24, 2020 · 名称: 2020人体解剖学图谱app破解版版本号: v2020.0.73 安卓内购版大小: 802M系统: 4.X及以上语言: 中文 [hr]简介: 2020人体解剖学图谱已付费完整版是专为解剖 …

医学 美术等人体有关的学生的福利 **human anatomy atlas**免费 - 吾 **…**
Apr 14, 2020 · 打开微软商店，搜索 human anatomy atlas 可以看到前面三个当中有两个是免费的，另外还有一个在打折。

求人体解剖学图谱 - 吾爱破解 - *52pojie.cn*
Jun 2, 2021 · [资源求助] 求人体解剖学图谱 [复制链接] 求人体解剖学图谱

人体解剖图谱（body Human Anatomy Atlas）安装 - 百度经验
Nov 10, 2018 · visible body Human Anatomy Atlas，3D人体解剖学图谱是美国波士顿的一家公司开发的人体构造解剖学图谱，通过这款app你可以详细了解人体的骨骼、内脏、血管等结构的 …

医学行业软件**Organon Anatomy**（我是搬运工） - 吾爱破解
Jul 25, 2019 · 我最近骨折 在医院里听病友说了一个软件可以模拟人类的骨骼进行活动，是3D效果。我向病友打听了这个软件。我在论坛里找到了相关的帖子，可是链接失效了 …

求**Complete Anatomy windows**版，谢谢 - 吾爱破解 **- 52pojie.cn**
Apr 2, 2021 · 求Complete Anatomy windows版，谢谢 [复制链接] … 下一页 » 1 2 / 2 页 下一页

Android - 『精品软件区』 - 吾爱破解 - 52pojie.cn
Mar 21, 2016 · 精品软件推荐，软件交流天地，汇集众多精彩评论，热心会员每日更新。找你所需要的，给你我分享的！这里不但有PC软件，安卓、iPhone等手机软件也统统包含。

Explore the anatomy of lower leg nerves

Back to Home