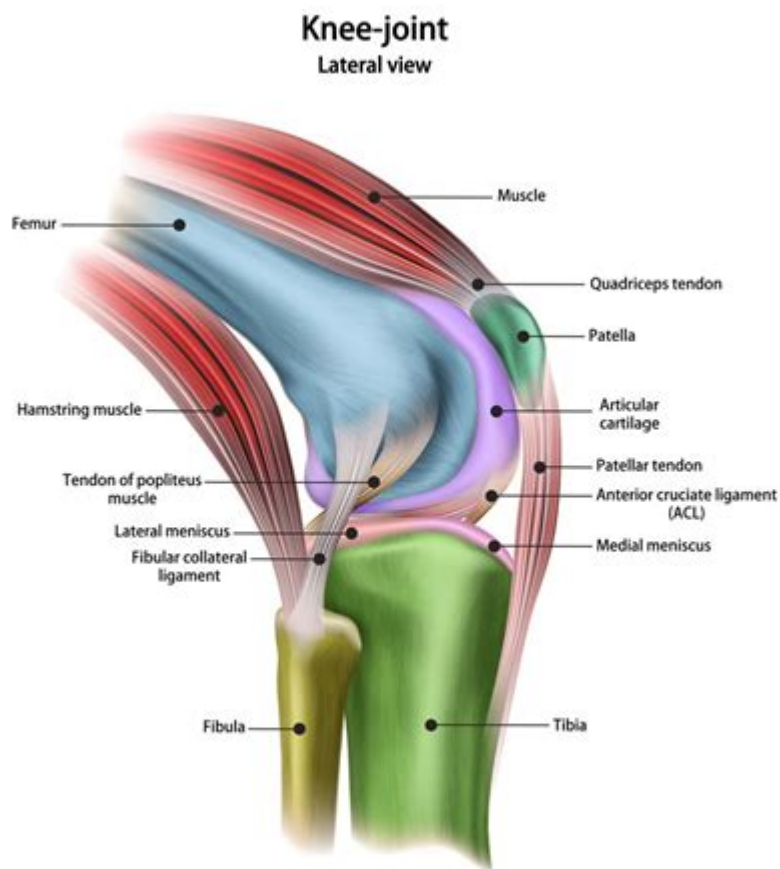


# Anatomy Of Lateral Knee



ANATOMY OF LATERAL KNEE IS A COMPLEX AND FASCINATING AREA OF HUMAN ANATOMY THAT PLAYS A CRUCIAL ROLE IN OUR ABILITY TO MOVE, RUN, AND ENGAGE IN VARIOUS PHYSICAL ACTIVITIES. THE KNEE JOINT IS ONE OF THE LARGEST AND MOST INTRICATE JOINTS IN THE BODY, CONSISTING OF BONES, LIGAMENTS, TENDONS, AND CARTILAGE. UNDERSTANDING THE ANATOMY OF THE LATERAL KNEE IS ESSENTIAL FOR ATHLETES, HEALTHCARE PROFESSIONALS, AND ANYONE INTERESTED IN KNEE HEALTH. THIS ARTICLE WILL EXPLORE THE COMPONENTS, FUNCTIONS, AND COMMON INJURIES ASSOCIATED WITH THE LATERAL ASPECT OF THE KNEE.

## COMPONENTS OF THE LATERAL KNEE

THE LATERAL KNEE COMPRISES SEVERAL KEY ANATOMICAL STRUCTURES THAT CONTRIBUTE TO ITS FUNCTION AND STABILITY. THESE COMPONENTS INCLUDE BONES, LIGAMENTS, TENDONS, AND MUSCLES.

### BONES

1. **FEMUR:** THE THIGH BONE, OR FEMUR, IS THE LARGEST BONE IN THE BODY AND HAS TWO CONDYLES (MEDIAL AND LATERAL) THAT ARTICULATE WITH THE TIBIA AND FIBULA AT THE KNEE JOINT.
2. **TIBIA:** THE TIBIA, OR SHIN BONE, IS THE LARGER AND STRONGER OF THE TWO BONES IN THE LOWER LEG. IT BEARS MOST OF THE BODY'S WEIGHT AND CONNECTS WITH THE FEMUR AT THE KNEE JOINT.

3. **FIBULA:** THE FIBULA RUNS PARALLEL TO THE TIBIA AND PROVIDES LATERAL STABILITY TO THE KNEE. IT DOES NOT BEAR SIGNIFICANT WEIGHT BUT SERVES AS AN ATTACHMENT POINT FOR LIGAMENTS AND MUSCLES.

## LIGAMENTS

LIGAMENTS ARE STRONG BANDS OF CONNECTIVE TISSUE THAT CONNECT BONES TO OTHER BONES, PROVIDING STABILITY TO THE KNEE JOINT. THE LATERAL KNEE CONTAINS:

1. **LATERAL COLLATERAL LIGAMENT (LCL):** THIS LIGAMENT RUNS ALONG THE OUTER SIDE OF THE KNEE, CONNECTING THE FEMUR TO THE FIBULA. IT STABILIZES THE KNEE DURING LATERAL MOVEMENTS AND PREVENTS EXCESSIVE VARUS (INWARD) FORCES.
2. **ANTERIOR CRUCIATE LIGAMENT (ACL):** ALTHOUGH PRIMARILY LOCATED IN THE CENTER OF THE KNEE, THE ACL PLAYS A CRUCIAL ROLE IN STABILIZING LATERAL MOVEMENTS BY PREVENTING THE TIBIA FROM SLIDING FORWARD RELATIVE TO THE FEMUR.
3. **POSTERIOR CRUCIATE LIGAMENT (PCL):** SIMILAR TO THE ACL, THE PCL IS LOCATED IN THE CENTER BUT HELPS STABILIZE THE KNEE IN CONJUNCTION WITH THE ACL, PARTICULARLY DURING BACKWARD MOVEMENTS.

## TENDONS

TENDONS CONNECT MUSCLES TO BONES AND ENABLE MOVEMENT AT THE KNEE JOINT. KEY TENDONS ASSOCIATED WITH THE LATERAL KNEE INCLUDE:

1. **ILIOTIBIAL BAND (IT BAND):** A THICK BAND OF CONNECTIVE TISSUE THAT RUNS ALONG THE OUTER THIGH FROM THE HIP TO THE TIBIA. IT PROVIDES STABILITY TO THE LATERAL KNEE AND ASSISTS IN KNEE FLEXION AND EXTENSION.
2. **PATELLAR TENDON:** THIS TENDON CONNECTS THE KNEECAP (PATELLA) TO THE TIBIA AND IS CRUCIAL FOR THE EXTENSION OF THE KNEE.

## MUSCLES

SEVERAL MUSCLES SUPPORT THE LATERAL KNEE BY CONTROLLING MOVEMENT AND PROVIDING STABILITY:

1. **BICEPS FEMORIS:** PART OF THE HAMSTRING GROUP, THIS MUSCLE IS LOCATED ON THE POSTERIOR LATERAL ASPECT OF THE THIGH AND HELPS FLEX THE KNEE.
2. **TENSOR FASCIAE LATAE (TFL):** THIS MUSCLE IS LOCATED ON THE LATERAL SIDE OF THE HIP AND ASSISTS IN HIP ABDUCTION AND STABILIZES THE KNEE THROUGH THE IT BAND.
3. **VASTUS LATERALIS:** THIS IS ONE OF THE QUADRICEPS MUSCLES LOCATED AT THE FRONT OF THE THIGH, CONTRIBUTING TO KNEE EXTENSION AND PROVIDING LATERAL STABILITY.

## FUNCTIONS OF THE LATERAL KNEE

UNDERSTANDING THE FUNCTIONS OF THE LATERAL KNEE IS ESSENTIAL FOR GRASPING ITS IMPORTANCE IN DAILY ACTIVITIES AND SPORTS. THE LATERAL KNEE PLAYS A CRITICAL ROLE IN:

1. **WEIGHT BEARING:** THE KNEE JOINT IS RESPONSIBLE FOR BEARING THE WEIGHT OF THE BODY DURING STANDING, WALKING, RUNNING, AND JUMPING. THE LATERAL STRUCTURES HELP DISTRIBUTE THIS WEIGHT EVENLY.
2. **MOVEMENT:** THE LATERAL KNEE ALLOWS FOR FLEXION AND EXTENSION, ENABLING ACTIVITIES SUCH AS WALKING, RUNNING, AND CLIMBING STAIRS. THE LIGAMENTS AND TENDONS PROVIDE STABILITY DURING THESE MOVEMENTS.

3. **STABILITY:** THE LATERAL COMPONENTS OF THE KNEE WORK TOGETHER TO MAINTAIN STABILITY DURING LATERAL MOVEMENTS, SUCH AS CUTTING, PIVOTING, AND SIDE-STEPPING, WHICH ARE COMMON IN MANY SPORTS.
4. **SHOCK ABSORPTION:** THE CARTILAGE WITHIN THE KNEE JOINT ACTS AS A CUSHION, ABSORBING SHOCK AND REDUCING THE IMPACT ON THE BONES DURING ACTIVITIES.

## COMMON INJURIES OF THE LATERAL KNEE

INJURIES TO THE LATERAL KNEE CAN OCCUR DUE TO TRAUMA, OVERUSE, OR UNDERLYING CONDITIONS. UNDERSTANDING THESE INJURIES IS CRUCIAL FOR PREVENTION AND TREATMENT.

### 1. LATERAL COLLATERAL LIGAMENT (LCL) INJURY

- **DESCRIPTION:** AN LCL INJURY OCCURS WHEN THE LIGAMENT IS STRETCHED OR TORN, OFTEN DUE TO A DIRECT BLOW TO THE INNER SIDE OF THE KNEE.
- **SYMPTOMS:** PAIN ON THE OUTER SIDE OF THE KNEE, SWELLING, INSTABILITY, AND DIFFICULTY WITH LATERAL MOVEMENTS.
- **TREATMENT:** REST, ICE, COMPRESSION, ELEVATION, PHYSICAL THERAPY, AND IN SEVERE CASES, SURGICAL INTERVENTION.

### 2. ILIOTIBIAL BAND SYNDROME (ITBS)

- **DESCRIPTION:** ITBS IS AN OVERUSE INJURY CHARACTERIZED BY INFLAMMATION OF THE IT BAND, OFTEN SEEN IN RUNNERS AND CYCLISTS.
- **SYMPTOMS:** LATERAL KNEE PAIN THAT WORSENS WITH ACTIVITY, TENDERNESS ALONG THE IT BAND, AND STIFFNESS.
- **TREATMENT:** REST, STRETCHING, STRENGTHENING EXERCISES, AND FOAM ROLLING CAN ALLEVIATE SYMPTOMS.

### 3. MENISCAL TEARS

- **DESCRIPTION:** THE MENISCUS IS A C-SHAPED CARTILAGE THAT CUSHIONS THE KNEE JOINT. TEARS CAN OCCUR DUE TO TWISTING MOTIONS OR DEGENERATION.
- **SYMPTOMS:** PAIN, SWELLING, CLICKING OR LOCKING SENSATIONS, AND DIFFICULTY BENDING OR STRAIGHTENING THE KNEE.
- **TREATMENT:** CONSERVATIVE MANAGEMENT INCLUDES REST AND PHYSICAL THERAPY, WHILE SEVERE CASES MAY REQUIRE ARTHROSCOPIC SURGERY.

## CONCLUSION

THE ANATOMY OF THE LATERAL KNEE IS A VITAL AREA OF STUDY FOR ANYONE INTERESTED IN HUMAN MOVEMENT AND JOINT HEALTH. UNDERSTANDING THE BONES, LIGAMENTS, TENDONS, AND MUSCLES THAT CONSTITUTE THIS REGION CAN PROVIDE INSIGHTS INTO ITS FUNCTIONS AND THE COMMON INJURIES THAT CAN OCCUR. BY MAINTAINING KNEE HEALTH THROUGH PROPER CONDITIONING, TRAINING, AND AWARENESS OF POTENTIAL INJURIES, INDIVIDUALS CAN ENHANCE THEIR PERFORMANCE AND REDUCE THE RISK OF KNEE-RELATED ISSUES. WHETHER YOU ARE AN ATHLETE OR SOMEONE LOOKING TO STAY ACTIVE, A SOLID UNDERSTANDING OF THE LATERAL KNEE'S ANATOMY IS ESSENTIAL FOR LIFELONG MOBILITY AND FUNCTION.

## FREQUENTLY ASKED QUESTIONS

## WHAT ARE THE MAIN ANATOMICAL STRUCTURES OF THE LATERAL KNEE?

THE MAIN ANATOMICAL STRUCTURES OF THE LATERAL KNEE INCLUDE THE FIBULA, LATERAL COLLATERAL LIGAMENT (LCL), ILIOTIBIAL BAND (ITB), LATERAL MENISCUS, AND THE BICEPS FEMORIS TENDON.

## HOW DOES THE LATERAL COLLATERAL LIGAMENT (LCL) FUNCTION IN KNEE STABILITY?

THE LCL PROVIDES LATERAL STABILITY TO THE KNEE BY RESISTING VARUS FORCES AND PREVENTING EXCESSIVE OUTWARD BENDING OF THE KNEE JOINT.

## WHAT ROLE DOES THE ILIOTIBIAL BAND PLAY IN LATERAL KNEE FUNCTION?

THE ILIOTIBIAL BAND HELPS STABILIZE THE KNEE DURING MOVEMENT AND ACTS AS A CONDUIT FOR MUSCLE ATTACHMENTS, PARTICULARLY FOR THE TENSOR FASCIAE LATAE AND GLUTEUS MAXIMUS MUSCLES.

## WHAT ARE COMMON INJURIES ASSOCIATED WITH THE LATERAL KNEE?

COMMON INJURIES INCLUDE LATERAL COLLATERAL LIGAMENT SPRAINS, ILIOTIBIAL BAND SYNDROME, AND LATERAL MENISCUS TEARS, OFTEN RESULTING FROM TRAUMA OR REPETITIVE STRESS.

## HOW CAN LATERAL KNEE INJURIES BE PREVENTED?

PREVENTION CAN INCLUDE STRENGTHENING EXERCISES FOR THE HIP AND THIGH MUSCLES, PROPER WARM-UP ROUTINES, AND AVOIDING SUDDEN CHANGES IN ACTIVITY LEVEL OR INTENSITY.

## WHAT IMAGING TECHNIQUES ARE BEST FOR ASSESSING LATERAL KNEE INJURIES?

MAGNETIC RESONANCE IMAGING (MRI) IS THE MOST EFFECTIVE METHOD FOR ASSESSING SOFT TISSUE INJURIES IN THE LATERAL KNEE, WHILE X-RAYS CAN HELP RULE OUT FRACTURES.

Find other PDF article:

<https://soc.up.edu.ph/31-click/Book?docid=Xmq39-3298&title=how-to-upload-to-youtube.pdf>

## Anatomy Of Lateral Knee

1.68 - 52pojie.cn

Apr 24, 2022 · <https://pan ...>

2020 app - 52pojie.cn

Mar 24, 2020 · 2020 app v2020.0.73 802M 4.X [hr] 2020 ...

human anatomy atlas - ...

Apr 14, 2020 · human anatomy atlas

52pojie.cn

Jun 2, 2021 · [ ] [ ]

body Human Anatomy Atlas -

Nov 10, 2018 · visible body Human Anatomy Atlas 3D app  
...

**Organon Anatomy** -

Jul 25, 2019 · 3D  
...

**Complete Anatomy windows** - - **52pojie.cn**

Apr 2, 2021 · Complete Anatomy windows [ ] ... » 1 2 / 2

**Android** - - **52pojie.cn**

Mar 21, 2016 · PC iPhone

1.68 - - *52pojie.cn*

Apr 24, 2022 · <https://pan ...>

**2020 app** - - **52pojie.cn**

Mar 24, 2020 · 2020 app v2020.0.73 802M 4.X [hr] 2020

human anatomy atlas - ...

Apr 14, 2020 · human anatomy atlas

- - **52pojie.cn**

Jun 2, 2021 · [ ] [ ]

body Human Anatomy Atlas -

Nov 10, 2018 · visible body Human Anatomy Atlas 3D app  
...

**Organon Anatomy** -

Jul 25, 2019 · 3D  
<https://www.52 ...>

**Complete Anatomy windows** - - **52pojie.cn**

Apr 2, 2021 · Complete Anatomy windows [ ] ... » 1 2 / 2

**Android** - - **52pojie.cn**

Mar 21, 2016 · PC iPhone

Explore the anatomy of the lateral knee

[Back to Home](#)