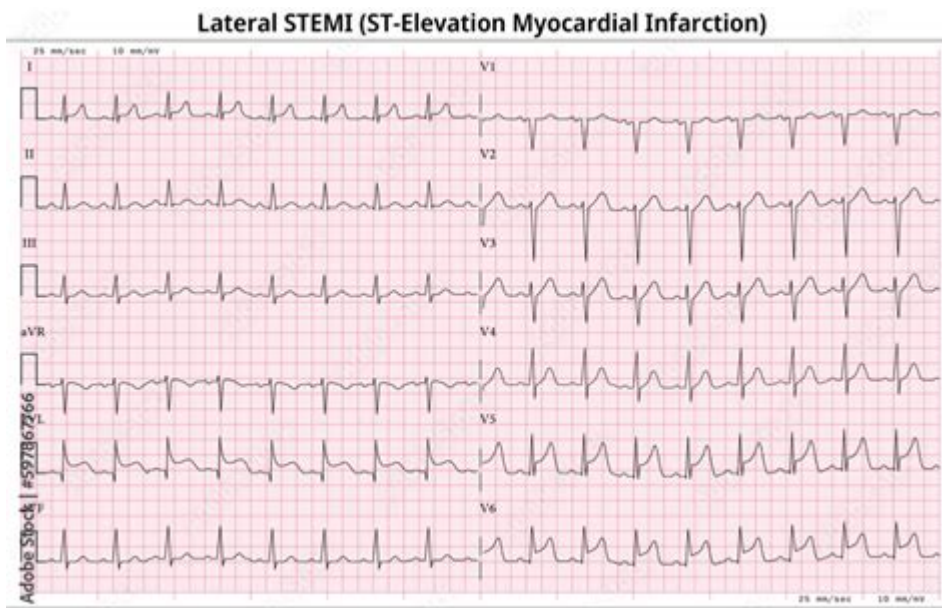


12 Lead Ecg Myocardial Infarction



12 lead ECG myocardial infarction is a critical diagnostic tool used in the assessment of patients suspected of experiencing a heart attack. This advanced electrocardiogram (ECG) technique provides comprehensive insights into the electrical activity of the heart, allowing medical professionals to detect myocardial infarction (MI) quickly and accurately. In this article, we will explore the importance of the 12 lead ECG in diagnosing myocardial infarction, the types of myocardial infarction, how to interpret the results, and the role it plays in patient management.

Understanding Myocardial Infarction

Myocardial infarction, commonly known as a heart attack, occurs when blood flow to a part of the heart is blocked, typically by a blood clot. This blockage can lead to damage or death of heart muscle tissue, emphasizing the need for rapid diagnosis and treatment. There are two primary types of myocardial infarction:

1. ST-Elevation Myocardial Infarction (STEMI)

STEMI occurs when there is a complete blockage of a coronary artery, leading to significant elevation of the ST segment on the ECG. This type of MI is a medical emergency that requires immediate intervention.

2. Non-ST-Elevation Myocardial Infarction (NSTEMI)

NSTEMI is characterized by partial blockage of a coronary artery, resulting in less severe ischemia and no significant ST elevation on the ECG. Although NSTEMI might appear less critical, it still requires prompt medical

attention.

The Role of 12 Lead ECG in Diagnosing Myocardial Infarction

The 12 lead ECG is the gold standard for diagnosing myocardial infarction. It captures electrical signals from different angles of the heart, providing a comprehensive view of its activity. The leads are positioned on the body to obtain a detailed representation of the heart's electrical conduction system.

Benefits of 12 Lead ECG

Using a 12 lead ECG to diagnose myocardial infarction offers several advantages:

- **Comprehensive Data:** The 12 leads provide a multi-dimensional view of the heart's electrical activity, helping identify ischemic changes.
- **Quick Diagnosis:** The ECG can be performed rapidly, allowing for immediate assessment and treatment decisions.
- **Non-Invasive:** This test is painless and non-invasive, making it suitable for patients of all ages.
- **Identifies Location of Infarction:** Different leads correspond to different areas of the heart, aiding in pinpointing the location of ischemia.

Interpreting the 12 Lead ECG

Interpreting the 12 lead ECG requires an understanding of the normal electrical conduction of the heart and the specific changes that indicate myocardial infarction. Here are the key steps in interpreting the results:

1. Assess the Rhythm

Begin by evaluating the heart rhythm. Look for regularity, rate, and the presence of any arrhythmias. A normal heart rate typically ranges from 60 to 100 beats per minute.

2. Examine the P Waves

P waves represent atrial depolarization. Check for their presence and morphology. Absence or abnormalities might indicate atrial enlargement or other issues.

3. Analyze the QRS Complex

The QRS complex reflects ventricular depolarization. A wider QRS may indicate a delay in conduction or a bundle branch block.

4. Evaluate the ST Segment

The ST segment is crucial for identifying myocardial infarction. Look for any elevation or depression:

- **ST Elevation:** Indicative of STEMI, typically seen in leads that correspond to the affected area.
- **ST Depression:** Often associated with NSTEMI, indicating subendocardial ischemia.

5. Review the T Waves

T waves represent ventricular repolarization. In the context of MI, T wave inversion may indicate ischemia, while peaked T waves can suggest hyperkalemia.

Recognizing Signs of Myocardial Infarction

In addition to ECG changes, clinicians should be aware of the common signs and symptoms associated with myocardial infarction, including:

- Chest pain or discomfort (often described as pressure or squeezing)
- Pain radiating to the arms, back, neck, jaw, or stomach
- Shortness of breath
- Nausea or vomiting
- Lightheadedness or fainting

Management of Myocardial Infarction

Prompt recognition and management of myocardial infarction are crucial for minimizing damage to the heart muscle. The initial management protocol typically includes:

1. Immediate Care

- Administer oxygen if the patient is hypoxemic.
- Establish intravenous access for medication administration.
- Monitor vital signs continuously.

2. Medications

Various medications may be administered, including:

- Antiplatelet agents (e.g., aspirin, clopidogrel)
- Thrombolytics (for STEMI)
- Anticoagulants
- Beta-blockers
- ACE inhibitors

3. Reperfusion Therapy

For patients with STEMI, urgent reperfusion therapy is critical. Options include:

- Percutaneous coronary intervention (PCI) to open blocked arteries.
- Thrombolytic therapy to dissolve clots.

4. Long-Term Management

Post-MI management focuses on rehabilitation and secondary prevention. This includes lifestyle modifications, cardiac rehabilitation programs, and medications to reduce the risk of future events.

Conclusion

In summary, the **12 lead ECG myocardial infarction** is an indispensable tool in the diagnosis and management of heart attacks. Its ability to provide detailed information about the heart's electrical activity enables healthcare providers to make timely and informed decisions. Understanding how to interpret ECG results and recognizing the signs of myocardial infarction are essential skills for clinicians. By implementing appropriate management strategies, we can significantly improve patient outcomes and reduce the impact of myocardial infarction on individuals and healthcare systems.

Frequently Asked Questions

What is a 12-lead ECG and why is it important in diagnosing myocardial infarction?

A 12-lead ECG is a test that records the electrical activity of the heart from 12 different angles. It is crucial in diagnosing myocardial infarction as it helps identify changes in the heart's electrical patterns that indicate areas of ischemia or damage.

What are the common ECG findings in ST-elevation myocardial infarction (STEMI)?

Common ECG findings in STEMI include ST-segment elevation in two or more contiguous leads, T-wave inversion, and the presence of abnormal Q waves, which indicate myocardial damage.

How can a 12-lead ECG differentiate between STEMI and NSTEMI?

A 12-lead ECG differentiates between STEMI and NSTEMI by showing ST-segment elevation in STEMI, whereas NSTEMI typically presents with ST-segment depression or T-wave inversion without significant elevation.

What role does the 12-lead ECG play in the triage of chest pain patients?

The 12-lead ECG is a vital tool in the triage of chest pain patients as it allows healthcare providers to quickly assess for signs of myocardial infarction, enabling timely intervention and treatment.

What are some limitations of 12-lead ECG in diagnosing myocardial infarction?

Limitations of the 12-lead ECG include false negatives in certain cases of myocardial infarction, difficulty in interpreting results in patients with pre-existing conditions or lead placement issues, and the potential for misinterpretation of non-cardiac causes of ST-segment changes.

How can the timing of an ECG affect the diagnosis of myocardial infarction?

The timing of an ECG is crucial because the appearance of changes can vary with the stage of myocardial infarction. Early in the event, there may only be T-wave changes, while ST-segment elevation may develop after several hours.

What is the significance of reciprocal changes on a 12-lead ECG in myocardial infarction?

Reciprocal changes on a 12-lead ECG indicate areas of the heart that are not affected by the infarction but are electrically opposite to the affected area. Their presence can support the diagnosis of myocardial infarction and help determine the extent of the damage.

Find other PDF article:

<https://soc.up.edu.ph/54-tone/files?dataid=LQD71-7784&title=smart-goals-occupational-therapy.pdf>

12 Lead Ecg Myocardial Infarction

i5-12450h 2025 i5-12450H ...

May 19, 2025 · i5-12450H Q1'22 12 12 i5 intel 10 2 ...

13 14 ? -

13 14 i9 i7 i7 ...

The Israel-Iran war by the numbers, after 12 days of fighti...

Jun 24, 2025 · The civilian toll Iran's ballistic missile attacks on Israel during the 12 days of war claimed the lives of ...

-

2011 1 ...

-

2011 1 ...

i5-12450h 2025 i5-12450H ...

May 19, 2025 · i5-12450H Q1'22 12 12 i5 intel 10 2 ...

13 14 ? -

13 14 i9 i7 i7 i5 13 14 12 i5 12400F i5 12600K i7 12700K ...

The Israel-Iran war by the numbers, after 12 days of fighting

Jun 24, 2025 · The civilian toll Iran's ballistic missile attacks on Israel during the 12 days of war claimed the lives of 28 people — all but one of them civilians — and wounded over 3,000 people.

-

2011 1 ...

-

2011 1 ...

"fastboot" -

: 10 ...

2025 7 RTX 5060

Jun 30, 2025 · 1080P/2K/4K RTX 5060 25 ...

1M1K -
~

...
1.
...

12
Nov 11, 2022 · 12 V

Discover how a 12 lead ECG can aid in diagnosing myocardial infarction. Learn more about its significance and interpretation in this informative article!

[Back to Home](#)